

# CASE REPORT

Nagoya J. Med. Sci. 77. 297 ~ 306, 2015

## RECURRENT ECTOPIC CRANIOPHARYNGIOMA IN THE SYLVIAN FISSURE THIRTY YEARS AFTER RESECTION THROUGH A PTERIONAL APPROACH: A CASE REPORT AND REVIEW OF THE LITERATURE

SHANNON W. CLARK<sup>1</sup>, MD; TYLER J. KENNING<sup>2</sup>, MD; and JAMES J. EVANS<sup>1</sup>, MD

<sup>1</sup>Thomas Jefferson University Department of Neurosurgery, Philadelphia, PA, USA  
<sup>2</sup>Albany Medical College Department of Neurosurgery, Albany, NY, USA

### ABSTRACT

Local recurrence of craniopharyngiomas after apparently complete resection occurs frequently. Ectopic recurrence remote from the original site has been reported in 18 adult patients. The interval between the original diagnosis and the time of recurrence varies widely in these reports (1–26 years). We report a case of an ectopic recurrence in the sylvian fissure of an adamantinomatous type craniopharyngioma 34 years after the initial presentation and 30 years after the last surgical resection. In addition to this being the latest reported ectopic recurrence, the location of this new lesion in the sylvian fissure is fairly rare, having been reported in only three other cases. We also reviewed the English literature for reports of ectopic recurrent craniopharyngiomas in order to conduct an analysis of surveillance and treatment strategies.

Key Words: metastatic craniopharyngioma, recurrent craniopharyngioma, craniopharyngioma treatment

### INTRODUCTION

Craniopharyngiomas are benign, partially cystic epithelial tumors of the sellar region thought to arise from remnants of Rathke's pouch and the craniopharyngeal duct. They account for 1.2–4.6% of all intracranial tumors with an annual incidence of 0.5–2.5 per million.<sup>1,2)</sup> In children, they are the most common non-neuroepithelial intra-axial neoplasm, accounting for 5–10% of these intracranial tumors.<sup>2,3)</sup> Craniopharyngiomas can occur anywhere along an axis from the sella turcica, pituitary gland, and pituitary stalk to the hypothalamus and floor of the third ventricle.<sup>1,4)</sup> Though histopathologically benign, these tumors can be locally invasive, and the rate of recurrence of craniopharyngiomas is reported to be as high as 57%.<sup>5)</sup> Most recurrences occur locally in the sellar region, but ectopic recurrences, both cranial and spinal, have been reported.

An ectopic recurrence of a craniopharyngioma is very rare and in most reported cases, occurs via direct seeding along the course of the previously utilized surgical approach.<sup>2)</sup> Although this is most prevalent among reported cases, recurrences remote from the surgical tract have led some to postulate that dissemination via the cerebrospinal fluid may be another mechanism for distant

---

Received: October 17, 2014; accepted: November 19, 2014

Corresponding author: Shannon Clark MD

Thomas Jefferson University Department of Neurosurgery, 1000 Walnut Street Apt 1506, Philadelphia, PA 19107 USA

Phone: 1-813-527-4403, Email: shann83@gmail.com

spread.<sup>4,6)</sup> A total of 44 cases of ectopic recurrent craniopharyngioma have been reported in the English literature, largely in the pediatric population. Only 18 cases occurred in adults. Ten adult cases had a remission duration of over ten years with the longest being 26 years;<sup>2,7,8)</sup> the majority of ectopic tumors recurred within five years of surgery.<sup>9-11)</sup> Here, we report a case of an ectopic recurrence of a craniopharyngioma 30 years after the last attempted surgical resection and 34 years after the patient's initial diagnosis and treatment.

## CASE REPORT

The patient is a 67 year-old female who was initially diagnosed at age 33 with a sellar/suprasellar craniopharyngioma. At that time, she presented with a bitemporal hemianopsia. Cranial CT demonstrated a partially calcified mass within the sella with suprasellar extension and compression of the overlying optic chiasm. A sublabial transsphenoidal approach for resection was utilized, but was unsuccessful due to the tumor's extensive calcifications and adherence to adjacent neurovascular structures.

Subsequently, a right pterional craniotomy was performed and an apparent gross total resection (GTR) was achieved. Pathologic examination demonstrated an adamantinomatous craniopharyngioma. Four years later in 1981, however, the patient's visual field deficit returned and imaging revealed a recurrence of the sellar/suprasellar mass. A left sided pterional craniotomy was utilized and a seemingly complete resection was achieved. As a result of these three operations, the patient had a persistent visual field deficit as well as transient diabetes insipidus. Recently, 30 years after her second transcranial surgery and 34 years after her initial diagnosis, surveillance cranial CT revealed a 1.7 × 1.2 cm ring-enhancing cystic mass in the region of the left sylvian fissure (Figure 1A). Of note, the patient was unable to obtain MRI secondary to the metallic wiring and vascular clips from her previous craniotomies. As the patient was not experiencing any new symptoms related to this new lesion, surveillance with follow-up imaging was planned. Over the course of three years, the lesion demonstrated incremental growth to a size of 3.2 × 2.2 cm (Figure 1B). Resection was recommended based on documented progression of the lesion and the need for tissue diagnosis.

Utilizing a portion of her previous left pterional incision, the patient's pre-existing temporal craniectomy was exposed and enlarged. After the dura was incised, the mass was clearly visualized in the sylvian fissure. The ectopic tumor had an appearance and consistency similar to sellar-suprasellar region craniopharyngioma and was extremely adherent to the surrounding brain and vasculature (Figure 2). After incising the surface and obtaining tumor contents for pathologic analysis, bipolar cautery was used to coagulate and thicken the exposed tumor capsule. Circumferential arachnoidal dissection was utilized to expose and mobilize the tumor. Care was taken to prevent spillage of tumor fluid into the resection cavity which could create the potential for further tumor seeding. The tumor was densely adherent to the middle cerebral artery, but was freed using sharp microdissection. After complete circumferential dissection the tumor was removed en-bloc.

Final pathology confirmed an adamantinomatous craniopharyngioma. This was the same histological type as the primary tumor (MIB-1 not available). Post operatively, patient recovered well without any new neurologic deficits and was discharged to home on postoperative day two. Immediate and three years follow up imaging demonstrated complete resection without any evidence of early recurrence (Figure 3). We are continuing with yearly follow up with contrasted CT head for first ten years.

## RECURRENT ECTOPIC CRANIOPHARYNGIOMA

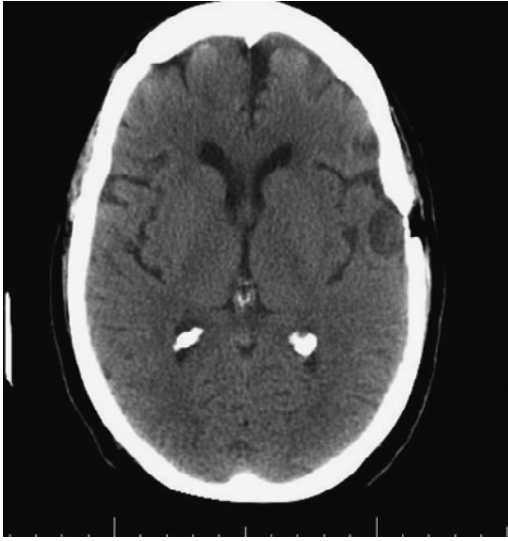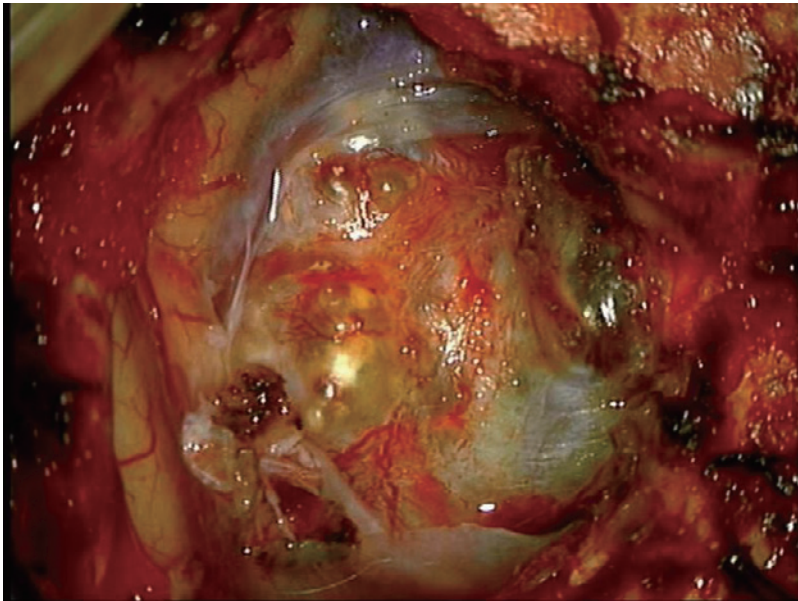


Fig. 1A

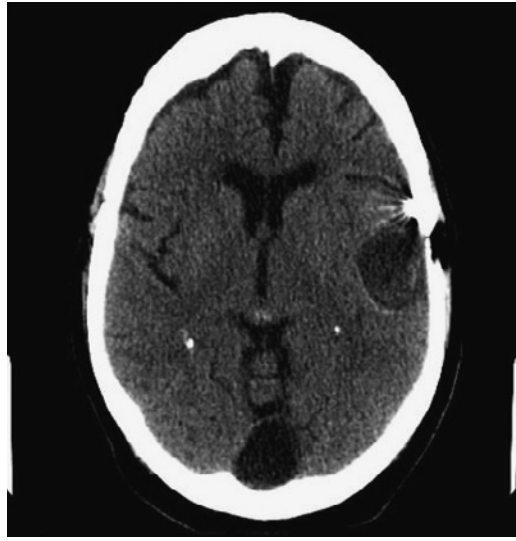

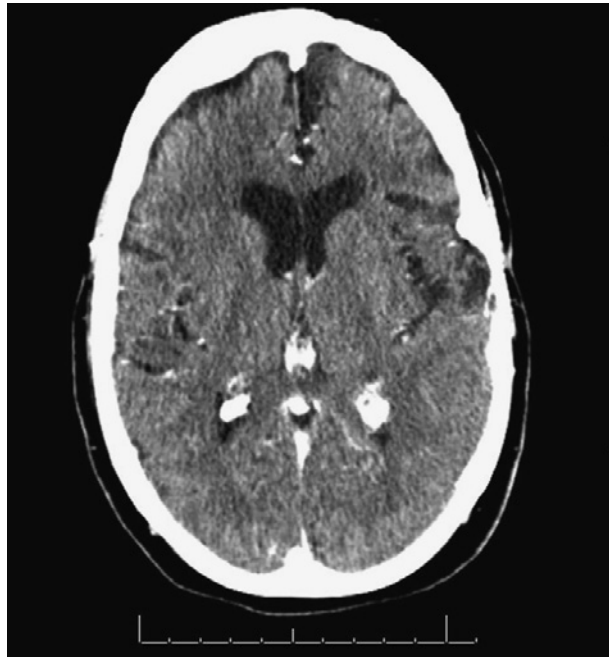Fig. 1B

**Fig. 1** A. Axial head CT w/o contrast showing incidentally found  $1.7 \times 1.2$  cystic lesion in left temporal lobe along the previous craniotomy tract. B. Axial head CT with contrast showing ring enhancing cystic lesion with increase in size to  $3.2 \times 2.2$  cm



**Fig. 2** Intraoperative photograph of the mass



**Fig. 3** Third year follow up CT head with contrast demonstrating no recurrence of the cystic mass at the surgical bed or anywhere else in brain.

## DISCUSSION

### *Epidemiology of recurrent craniopharyngioma*

Local recurrence of craniopharyngiomas after seemingly total resection may be as high as 53% with a mean time to recurrence of 1–3 years after the initial surgery.<sup>2,12)</sup> Ectopic recurrence of craniopharyngiomas, however, appears to be a rare occurrence with only 44 reports in the literature. In one of the largest series of craniopharyngiomas, Elliott *et al.* described four ectopic recurrences among the 86 consecutive children undergoing GTR.<sup>4)</sup> Overall, the reported rate of ectopic recurrence is widely variable and may account for 3–27 % of all total recurrences.<sup>4,7,13-15)</sup> The time to recurrence has been reported to be between 1 month and 26 years from the last surgery,<sup>4,16)</sup> and the mean time to recurrence of ectopia is 6.8 years, which is much longer than that of local recurrence (reported to be 12 months with range of 2–36 months).<sup>2)</sup> Thus, it is likely that with extended time of surveillance, the incidence of distant recurrence may be found to be higher than reported.

### *Mechanism ectopic of recurrence*

The mechanism of ectopia in craniopharyngioma has been attributed to two pathways. First, seeding along the surgical route during primary resection appears to be the most common route of ectopic spread. In greater than half of the reported cases, this is speculated to be the cause.<sup>10,13,14,14,17-22)</sup> It must therefore be emphasized that meticulous handling of tumor specimens and preservation of tissue planes are essential during craniopharyngioma resection. This will serve to not only limit perioperative surgical morbidity, but may also help to prevent ectopic recurrence.

The second source of ectopic spread is thought to be via tumor cell spillage into the cere-

brospinal fluid (CSF). This may allow viable tumor cells to migrate within the subarachnoid and even the intraventricular spaces.<sup>7,11,23,24,24-27)</sup> A report of craniopharyngioma recurrence in the lumbar cistern supports CSF dissemination as a source.<sup>27,28)</sup> Furthermore, a case describing cytologically confirmed CSF contamination has been documented after resection of a craniopharyngioma.<sup>29)</sup> With respect to the mechanism of this tumor, authors believe that it was likely due to direct dissemination from the previous left sided pterional craniotomy carried out years ago for the initial sellar recurrence. This is because the ectopic recurrence occurred at the old surgical route.

#### *Literature review of 45 reported ectopic cases*

To date, a total of 44 cases of ectopic recurrent craniopharyngiomas have been reported: 26 are pediatric and 18 are adult onset tumors. Table 1 provides details of the 44 previously reported ectopic metastases, as well as the present case. For patients who had multiple recurrences and treatments, the time to recurrence of ectopia is reported as the interval between last resection until the detection of the ectopic tumor on an imaging study.

Children have slightly longer intervals to recurrence with a mean of 7.3 years and a median of 4.5 years (standard deviation of 7.7 years).<sup>1,4,6,12,13,15,16,17,19,21,24,25,27,28,33)</sup> In adults, the mean was 6.7 years and the median was 3.5 years (standard deviation of 6.9 years).<sup>6,7,12,13,14,26,30,31,32,47-52)</sup> Eleven of the 44 cases (25%) had longer than 10 years of remission. Although 35% of all craniopharyngiomas occur in children,<sup>30)</sup> the majority (27 out of 44 or 61%) of the reported ectopic recurrences occurred among pediatric patients.<sup>30)</sup> This finding is likely attributable to a longer duration of follow-up in this patient population.<sup>30)</sup> Ectopic recurrences occur nearly equally in males and females, paralleling the gender distribution of the original disease.

Histologically, all the children with ectopic recurrences had adamantinomatous type craniopharyngiomas while in adults, 3 of 13 cases (23%) with known pathology were papillary type. Due to the small sample size and the fact that six cases had unknown or unreported histology, it is not possible to make any conclusions regarding the propensity of ectopia between adamantinomatous or papillary type craniopharyngiomas. It is believed that papillary histology results in a more indolent disease course and a lower rate of recurrence following complete resection.<sup>25,31)</sup> It is unclear, however, if the predominance of adamantinomatous tumors among ectopias represents different biology or simply the greater prevalence of the adamantinomatous type.

Regarding the mechanism of craniopharyngioma ectopic spread, 20 cases were speculated to be via CSF dissemination, 24 cases via direct seeding of surgical pathway and one case was believed to have both. The mean time to recurrence for CSF dissemination was  $8.7 \pm 7.6$  years while in cases with seeding of the surgical pathway, it was  $5.2 \pm 6.9$  years. Interestingly, the two cases of recurrence in the lumbar cistern via

CSF dissemination were discovered 0.5 and 1.5 years after the initial resection.<sup>27,28)</sup>

It is widely acknowledged that incomplete resection of craniopharyngiomas is the most significant risk factor for recurrence.<sup>1)</sup> According to a multicenter trial of 117 patients, 69% had progression or local recurrence after STR and only 36% after GTR.<sup>2,32)</sup> In distant recurrences, however, our review demonstrates that in the 37 cases reporting on extent of resection, 22 (59%) had a GTR of the initial lesion, a finding suggesting that the distant recurrence may not be related to the extent of the initial resection. This higher prevalence of ectopic recurrence after GTR may be a result of more aggressive surgery and/or a longer operative time, allowing for a greater tumor volume to be manipulated and exposed to the surgical tract and/or cerebrospinal fluid pathways. Even though 12 out of 15 patients (80%) undergoing STR required subsequent surgical procedures for tumor progression or recurrence, it appears that multiple surgeries may not be as great a risk factor as a single aggressive GTR. Among the STR cases, patients treated with radiation therapy had 7.5 years of mean time to recurrence while the five patients not treated

**Table 1** summary of reviews for all 45 reported cases of ectopic recurrence of craniopharyngioma. GTR= gross total resection, STR = subtotal resection. RT = radiation therapy; a = adamantinomatous; p = papillary; (m) = multiple surgical resection

Study	time to recur	age at initial dx	gender	original tx	Prior RT	path type	location of ectopia	Speculated Path way of spread
Hann <i>et al.</i> , 2014	30	33	F	GTR (m)	N	A	L temporal in sylvian fissure	seeding along tract
Keohane <i>et al.</i> (21)	26	7	F	-	Y	-	L cerebellopontine angle	subarachnoid spread
Yamada <i>et al.</i> (29)	23	17	F	STR (m)	Y	A	L frontal mass	subarachnoid spread
Gokalp <i>et al.</i> (27)	20	3	M	GTR	N	-	Fourth ventricle	subarachnoid spread
Malik <i>et al.</i> (24)	19	6	M	STR (m)	Y	A	R frontal	seeding along tract
Bikmas <i>et al.</i> (12)	15	37	F	-	N	A	prepontine cystem	subarachnoid spread
de Blank <i>et al.</i> (1)	15	5	F	GTR	Y	A	L cerebellopontine angle	subarachnoid spread
Bikmaz <i>et al.</i> (12)	11	12	M	STR (m)	Y	-	R cerebellopontine angle	subarachnoid spread
Schmalisch <i>et al.</i> (13)	10	32	M	GTR	N	A	R parietal	subarachnoid spread
Schmalisch <i>et al.</i> (13)	10	11	M	GTR	N	A	R sylvian fissure	seeding along tract
Elliotte <i>et al.</i> (4)	10	3	F	GTR (m)	N	A	prepontine cystem	subarachnoid spread
Bikmas <i>et al.</i> (12)	9	32	M	GTR	-	P	R frontal intraparenchymal	seeding along tract
Novak <i>et al.</i> (30)	8	48	M	-	Y	-	Post fossa	subarachnoid spread
Gupta <i>et al.</i> (47)	7	66	M	-	N	A	L parietoccipital and L frontal	subarachnoid spread
Tomita <i>et al.</i> l(26)	7	23	F	STR	Y	-	Post fossa	subarachnoid spread
Baba <i>et al.</i> (28)	7	7	F	- (m)	N	A	Clivus to upper cervical cord	subarachnoid spread
Freitag <i>et al.</i> l(7)	5	61	F	-	N	-	R frontal	seeding along tract
Fuentes <i>et al.</i> (6)	5	32	M	GTR	N	A	R frontal	seeding along tract
Liu <i>et al.</i> l (14)	4	65	F	GTR	N	A	R frontal	seeding along tract
Romani <i>et al.</i> (15)	4	17	F	STR (m)	Y	A	R frontomedial	seeding along tract
Frangou <i>et al.</i> (16)	4	10	M	STR (m)	Y	A	R temp fossa and R parietal	subarachnoid spread
Jeong <i>et al.</i> (25)	4	8	F	GTR	N	A	R frontal	seeding along tract
Ito <i>et al.</i> (48)	3	32	M	GTR	N	A	R temporal	subarachnoid spread
Fuentes <i>et al.</i> (6)	3	11	M	GTR	N	-	along R frontal surgical tract	seeding along tract
Fuentes <i>et al.</i> (6)	3	9	M	GTR	N	A	R temp and R front	seeding along tract
Novegno <i>et al.</i> (23)	3	6	M	GTR (m)	N	A	L frontobasal	seeding along tract
Elmaci <i>et al.</i> (49)	2	62	F	GTR	N	P	L tempriparietal	subarachnoid spread
Ragowansi <i>et al.</i> (50)	2	45	M	GTR (m)	N	-	Ant. R sylvian fissure	seeding along tract
Kawaguchi <i>et al.</i> (51)	2	35	F	- (m)	Y	A	L frontal lobe	seeding along tract
Lee <i>et al.</i> (31)	2	31	M	GTR (m)	N	-	R temp lobe	seeding along tract
Schmalich <i>et al.</i> (13)	2	23	F	STR (m)	N	A	R frontal craniectomy	seeding along tract
Israel <i>et al.</i> (17)	2	12	M	GTR	N	-	Frontal	seeding along tract
Isael <i>et al.</i> (17)	2	10	M	GTR	N	-	R fontal and subfrontal	subarachnoid spread
Barloon <i>et al.</i> (18)	2	5	M	STR (m)	Y	A	R frontal	seeding along tract
Wang <i>et al.</i> (19)	2	3	M	STR	Y	A	R frontal	seeding along tract
Elliotte <i>et al.</i> (4)	2	2	M	STR (m)	N	A	L cerebellopontine angle	subarachnoid spread
Nomura <i>et al.</i> (33)	1.67	17	F	STR (m)	Y	A	R frontotemporal	Both
Elliotte <i>et al.</i> (4)	1.67	3	F	GTR	N	A	R sylvian fissure	seeding along tract
Lee <i>et al.</i> (31)	1.5	26	M	STR	Y	P	Lumbar space	subarachnoid spread
Lermen <i>et al.</i> (32)	0.5	39	M	STR (m)	N	A	lumbar spinal	subarachnoid spread
Bianco <i>et al.</i> (52)	0.17	26	F	STR (m)	N	S	L temp lobe	seeding along tract
Ishii <i>et al.</i> (22)	0.17	2	M	GTR (m)	N	A	ommaya tract	seeding along tract
Elliotte <i>et al.</i> (4)	0.08	6	M	STR (m)	N	A	L subfrontal	subarachnoid spread
Tomita <i>et al.</i> (26)	-	Child	-	GTR	N	-	R forontal pole	seeding along tract
Kim <i>et al.</i> (10)	-	Child	-	-	-	-	cerebellopontine angle	-

with radiation after STR had relapse in less than a year. This suggests that radiation therapy is likely beneficial in delaying the disease course, even in ectopic recurrences, especially in cases of suboptimal surgical treatment. The current findings further support the benefit of radiation therapy in preventing or delaying local recurrences as well as those distant from the original site.<sup>1,33)</sup>

#### *Treatment of ectopic recurrence*

Although the majority of craniopharyngioma recurrences, both local and ectopic, are detected by surveillance cranial imaging, the measurement of urinary matrix metalloproteinase levels may aid in the diagnosis.<sup>1,34)</sup> Discovering the recurrence of craniopharyngiomas early prior to extensive pial invasion and adhesion to neurovascular structures will likely result in the greatest chance for a maximal resection. The main modalities of recurrent craniopharyngioma treatment include surgery alone, surgery (mostly when resection is subtotal) with adjuvant radiotherapy, and radiation therapy alone. Some surgeons believe that STR with adjuvant radiation therapy provides a lesser risk of acute and long-term endocrine, hypothalamic, neurocognitive, and functional complications.<sup>25)</sup> In the case of local recurrence, the likelihood of achieving a GTR on re-operation decreases to 0%–25%.<sup>1)</sup> Additionally, the morbidity and mortality related to repeat surgery may be higher.<sup>35,36)</sup> Radiation therapy after repeat resection may maintain 72% of patients progression free for 10 years.<sup>37)</sup> However, it is difficult to estimate what is the best modality of preventing second recurrence based on the reported cases because most of the recurrent case series have relatively small number of patients. Libunius *et al.* reported second recurrences in up to 14% to 33% of patients who underwent surgery for recurrent disease. Kalapurakal *et al.* presented a series of 14 paediatric patients with radiological and clinically recurrent disease post primary surgical resection. Of whom seven were treated with surgery and six had recurrence (86%) and one out of the five patients treated with radiation had progression of disease. Other series report 5-year and 10-year survival rates of 30% and 18% respectively for surgery and 71% and 77% for surgery plus radiation,<sup>8)</sup> suggesting beneficial role of adjuvant radiation therapy in reducing mortality. In a series of 17 radiologically diagnosed recurrent tumors, Karavitaki *et al.* treated eight (47%) with STR alone, three (18%) with STR plus radiotherapy and six (35%) with radiotherapy only. Recurrence-free survival at 30 months for these three groups was 50%, 100% and 83% respectively ( $p = 0.04$ ).<sup>9)</sup> Thus, as with primary tumor treatment, adjuvant radiation therapy in addition to surgical resection seems to be the most promising treatment option to minimize recurrence or to extend the disease free period.

For ectopic craniopharyngioma recurrences, authors believe surgical resection should be the treatment of choice when possible. Most of the reported surgical treatments of ectopic recurrent craniopharyngiomas are basal transcranial approaches because of their predominant locations are in the chiasmatic cistern. Despite upto 40% of craniopharyngiomas are resected via transsphenoidal approach, there are no reports about ectopic recurrence that required a transsphenoidal approach for the resection.<sup>13)</sup> Elliott *et al.*, summarized the treatment of 31 reported cases of ectopic recurrence. In 22 patients (81%) undergoing surgery, a GTR was achieved and provided adequate disease control for the duration of follow-up. This remission rate (79%) is similar to the reported rates with GTR for primary suprasellar craniopharyngiomas. In this series, the underlying factors for subtotal resection of ectopic recurrences included recurrence involving brainstem and deep white matter as well as significant medical comorbidities precluding extensive surgical resection.<sup>4)</sup>

If the recurrence is primarily cystic and GTR is not feasible, gamma knife radiotherapy, intracystic therapies, including intracavitary irradiation or chemotherapy with bleomycine or interferon have been reported.<sup>38-40)</sup> However, currently, stereotactic radiotherapy, intracavitary bleomycin, and systemic chemotherapy remain investigational treatment modalities for this challenging disease.

## CONCLUSION

Ectopic craniopharyngioma recurrence is a rare event with only 44 previously reported cases. In the present case, an ectopic craniopharyngioma was diagnosed in the sylvian fissure along a prior surgical corridor thirty years after a pterional approach for a sellar/suprasellar tumor resection. This report emphasizes the importance of long term follow up even after apparent GTR. Approximately one third of the reported cases occurred ten years or later from the original diagnosis. Ectopic recurrence should be considered in patients with a history of craniopharyngioma resection and a new mass lesion remote from the original tumor bed. Lifelong follow-up of these patients is therefore recommended.<sup>41)</sup> Annual MRI imaging should be obtained after GTR and at 6-month intervals after STR.<sup>41,42)</sup> Ectopic recurrences appear to be amenable to curative resection with low morbidity if tumor specimens are handled carefully.

## FINANCIAL DISCLOSURE/CONFLICT OF INTEREST

The authors have no financial disclosure for this work.

The authors have no conflicts of interest with regard to this research or its funding.

## REFERENCES

- 1) Winn HR, Youmans JR. *Youmans neurological surgery*. Philadelphia, Pa.: W.B. Saunders; 2004.
- 2) de Blank PM, Minturn JE. A rare case of ectopic recurrence of a craniopharyngioma diagnosed 17 years after initial presentation. *Journal of Pediatric Hematology/Oncology*, 2011; 33(5): 392–397.
- 3) Baskin DS, Wilson CB. Surgical management of craniopharyngiomas. *J Neurosurg*, 1986; 65(1): 22–27. <http://dx.doi.org/10.3171/jns.1986.65.1.0022>. doi: 10.3171/jns.1986.65.1.0022.
- 4) Elliott RE, Moshel YA, Wisoff JH. Surgical treatment of ectopic recurrence of craniopharyngioma. *Journal of Neurosurgery: Pediatrics*, 2009; 4(2): 105–112. <http://dx.doi.org/10.3171/2009.3.PEDS0948>. doi: 10.3171/2009.3.PEDS0948.
- 5) Dhellemmes P, Vinchon M. Radical resection for craniopharyngiomas in children: Surgical technique and clinical results. *Journal of pediatric endocrinology & metabolism. JPEM*, 2006; 19: 329–35.
- 6) Lee DK, Jung HW, Kim DG, Paek SH, Gwak HS, Choe G. Postoperative spinal seeding of craniopharyngioma. case report. *J Neurosurg*, 2001; 94(4): 617–20.
- 7) Bikmaz KMD, Guerrero CAMD, Dammers RMD, Ph.D., Krisht AFMD, Husain MMMD. ECTOPIC RECURRENCE OF CRANIOPHARYNGIOMAS: CASE REPORT. *Neurosurgery*, 2009; 64(2): E382–E383.
- 8) Schmalisch K, Beschoner R, Psaras T, *et al.* Postoperative intracranial seeding of craniopharyngiomas: Report of three cases and review of the literature. *Acta Neurochir (Wien)*, 2010; 152: 313–319.
- 9) Liu JMMD, Garonzik IMMD, Eberhart CGMD, Ph.D., Sampath PMD, Brem HMD. Ectopic recurrence of craniopharyngioma after an interhemispheric transcallosal approach: Case report. *Neurosurgery*, 2002; 50(3): 639–645.
- 10) Romani R, Niemelä M, Celik O, *et al.* Ectopic recurrence of craniopharyngioma along the surgical route: Case report and literature review. *Acta Neurochir (Wien)*, 2010; 152: 297–302.
- 11) Frangou E, Tynan J, Robinson C, *et al.* Metastatic craniopharyngioma: Case report and literature review. *Childs Nerv Syst*, 2009; 25: 1143–1147.
- 12) Ohmori K, Collins J, Fukushima T. Craniopharyngiomas in children. *Pediatr Neurosurg*, 2007; 43(4): 265–278.
- 13) Tomita T, McLone D. Radical resections of childhood craniopharyngiomas. *Pediatr Neurosurg*, 1993; 19: 6–14.
- 14) Fuentes S, Metellus P, Dufour H, Do L, Grisoli F. Postoperative intracranial seeding of craniopharyngioma. three case reports and a review of the literature. *Neurochirurgie*, 2002; 48: 345–350.
- 15) Caldarelli M, Massimi L, Tamburrini G, Cappa M, Di Rocco C. Long-term results of the surgical treatment of craniopharyngioma: The experience at the policlinico gemelli, catholic university, rome. *Child's nervous system : ChNS : official journal of the International Society for Pediatric Neurosurgery*, 2005; 21(8–9):



## RECURRENT ECTOPIC CRANIOPHARYNGIOMA

- 8–9.
- 16) Keohane C, Hally M, Ryder D. Late recurrence of craniopharyngioma in the cerebellopontine angle in a fertile woman. *J Neurol Neurosurg Psychiatr*, 1994; 57: 873–874.
  - 17) Ishii K, Sugita K, Kobayashi H, et al. Intracranial ectopic recurrence of craniopharyngioma after ommaya reservoir implantation. *Pediatr Neurosurg*, 2004; 40(5): 230–233.
  - 18) Barloon TJ, Yuh WT, Sato Y, Sickels WJ. Frontal lobe implantation of craniopharyngioma by repeated needle aspirations. *AJNR. American journal of neuroradiology*, 1988; 9(2).
  - 19) Novegno F, Di Rocco F, Colosimo Jr C, Lauriola L, Caldarelli M. Ectopic recurrences of craniopharyngioma. *Child's nervous system : ChNS : official journal of the International Society for Pediatric Neurosurgery*, 2002; 18(9–10): 9–10.
  - 20) Malik JM, Cosgrove GR, VandenBerg SR. Remote recurrence of craniopharyngioma in the epidural space. *J Neurosurg*, 1992; 77(5): 804–807. <http://dx.doi.org/10.3171/jns.1992.77.5.0804>. doi: 10.3171/jns.1992.77.5.0804.
  - 21) Jeong I, Lee J, Moon K, et al. Ectopic recurrence of craniopharyngioma: A case report and review of the literature. *J Neuro Oncol*, 2006(79): 191–195.
  - 22) Israel ZH, Pomeranz S. Intracranial craniopharyngioma seeding following radical resection. *Pediatr Neurosurg*, 1995; 22(4): 210–3.
  - 23) Gokalp H, Egemen N, Ildan F, et al. Craniopharyngioma of the posterior fossa. *Neurosurgery*, 1991; 29: 446–448.
  - 24) Baba M, Iwayama S, Jimbo M, et al. Cystic craniopharyngioma extending down into the upper cervical spinal canal. *No shinkei geka*, 1978; 6: 687.
  - 25) Yamada Y, Haraoka J, Akimoto J. Ectopic recurrence of craniopharyngioma. *Neurologia medico-chirurgica*, 2006; 46(12): 598–600.
  - 26) Novák Z, Chrastina J, Feitová V, et al. Minimally invasive treatment of posterior fossa craniopharyngioma by means of navigated endoscopy. *minim invasive neurosurg*. 2008; 51: 165–168. *Minim Invasive Neurosurg*, 2008; 51: 165–168.
  - 27) Lee JH, Kim CY, Kim DG, Jung HW. Postoperative ectopic seeding of craniopharyngioma. case illustration. *J Neurosurg*, 1999; 90(4).
  - 28) Lermen O., Frank S., Hassler W. Postoperative spinal recurrence of craniopharyngioma. *Acta Neurochir. Acta Neurochirurgica*, 2010; 152(2): 309–311.
  - 29) Nomura H, Kurimoto M, Nagai S, et al. Multiple intracranial seeding of craniopharyngioma after repeated surgery--case report. *Neurol Med*, 2002; 42(6): 268–71.
  - 30) Louis DN, Deutsches Krebsforschungszentrum Heidelberg., International Agency for Research on Cancer., World Health Organization. WHO classification of tumours of the central nervous system. Updated 2007.
  - 31) Liubinas SV, Munshey AS, Kaye AH. Management of recurrent craniopharyngioma. *Journal of Clinical Neuroscience*, 2011; 18(4): 451–457.
  - 32) Müller HL, Gebhardt U, Pohl F, Flentje M, Emser A, Warmuth-Metz M, Kolb R, Calaminus G, Sörensen N. Relapse pattern after complete resection and early progression after incomplete resection of childhood craniopharyngioma. *Klin Padiatr*, 2006; 218(6): 315–320.
  - 33) Carmel PW, Antunes JL, Chang CH. Craniopharyngiomas in children. *Neurosurgery*, 1982; 11(3): 382–9.
  - 34) Smith ER, Manfredi M, Scott RM, Black PM, Moses MA. A recurrent craniopharyngioma illustrates the potential usefulness of urinary matrix metalloproteinases as noninvasive biomarkers: Case report. *Neurosurgery*, 2007; 60(6): 1148–9.
  - 35) Fahlbusch R, Honegger J, Paulus W, Huk W, Buchfelder M. Surgical treatment of craniopharyngiomas: Experience with 168 patients. *J Neurosurg*, 1999; 90(2): 237–50.
  - 36) Karavitaki N, Brufani C, Warner JT, et al. ORIGINAL ARTICLE: Craniopharyngiomas in children and adults: Systematic analysis of 121 cases with long-term follow-up. *Clin Endocrinol (Oxf)*, 2005; 62(4): 397–409.
  - 37) Jose CC, Rajan B, Ashley S, Marsh H, Brada M. Radiotherapy for the treatment of recurrent craniopharyngioma. *Clin Oncol (R Coll Radiol)*, 1992; 4(5): 287–9.
  - 38) Cavalheiro S, Dastoli PA, Silva NS, Toledo S, Lederman H, da Silva MC. Use of interferon alpha in intratumoral chemotherapy for cystic craniopharyngioma. *Child's nervous system : ChNS : official journal of the International Society for Pediatric Neurosurgery*, 2005; 21(8–9): 8–9.
  - 39) Hasegawa T, Kondziolka D, Hadjipanayis CG, Lunsford LD. Management of cystic craniopharyngiomas with phosphorus-32 intracavitary irradiation. *Neurosurgery*, 2004; 54(4): 813–20.
  - 40) Julow, J., et al., *Long-term results and late complications after intracavitary yttrium-90 colloid irradiation of recurrent cystic craniopharyngiomas. Neurosurgery*, 2007. 61(2): p. 288–95; discussion 295–6.

- 41) Scott RM. Craniopharyngioma: A personal (boston) experience. *Child's nervous system : ChNS : official journal of the International Society for Pediatric Neurosurgery*, 2005; 21(8-9): 8-9.
- 42) Honegger J., Tatagiba M. Craniopharyngioma surgery. *Pituitary Pituitary*, 2008; 11(4): 361-373.