
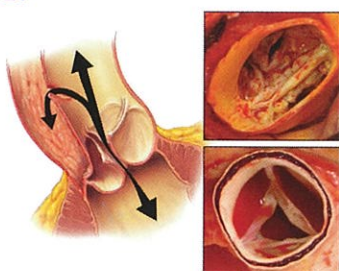


JTCVS

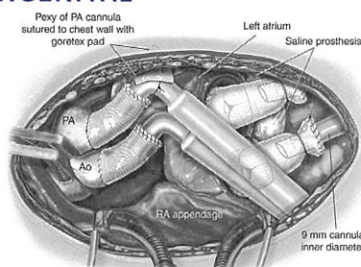


ADULT



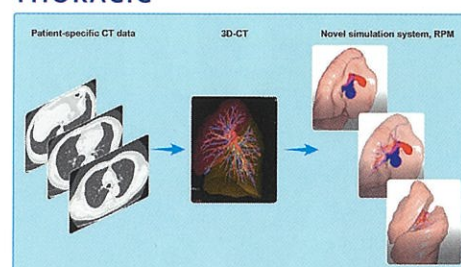
Dissection with BAV or TAV See page 768

CONGENITAL



Total artificial heart in an infant See page 1075

THORACIC



Virtual dynamic image from 3D-CT See page 1130

ADULT

Aorta: Significance of BAV in acute type A dissection <i>Mennander</i>	760
Commentary: Follow principles & do what you need to do <i>Preventza</i>	768
Commentary: When is a simple tube graft a disservice? <i>Chikwe</i>	770
Aorta: Axillary cannulation reduces embolic stroke <i>Kim & Joo</i>	772
Commentary: Always do right <i>Minatoya</i>	779
Commentary: Does axillary cannulation prevent emboli? <i>Gleason</i>	781
Aorta: Altered ascending 4D MRI flow in VSARR pts <i>Oechtering</i>	798
Commentary: Valuable flow patterns in VSARR <i>Asai</i>	811
HCM: LV ejection before & after AVR + myectomy <i>Cui & Schaff</i>	844
MCS: RV function & residual MR after LVAD and RV failure <i>Tang</i>	897
Commentary: When suction alone is not enough <i>Bechtel</i>	906
Commentary: A tale of two valves <i>Bhama</i>	908
MCS: Invited Expert Opinion: LVAD double whammy <i>Hyden & Drakos</i>	910
Commentary: Alive no pulse & bleeding <i>Abdelsattar & Crestanello</i>	916
PM: PO urinary profiles, AKI, & mortality <i>Shen & Ding</i>	918
Commentary: PO AKI: Is "-omics" right way? <i>Barberini & Miceli</i>	927
Commentary: Keep your ion urine—to predict PO AKI? <i>Zarbock</i>	928
PM: Impact of obesity on PO AFib burden <i>Serban & de Groot</i>	930
Commentary: Obesity & surgery: Double trouble <i>Ali</i>	939
Commentary: Obesity & PO AFib: Weight continues <i>Holst</i>	941
PM: Neuroprotection: Optimize cerebral oxygenation <i>Uysal & Reich</i>	943
Commentary: To prevent PO cognitive decline <i>Aglio & Mizuguchi</i>	954
Commentary: Optimizing oxygenation & outcomes <i>Grocott</i>	956
Education: CT surgery training in the Nordic countries <i>Mennander</i>	1002
Commentary: Nordic CT training: Common challenges <i>Nissen & Nguyen</i>	1009

CONGENITAL

Atrioventricular Septal Defect: Repair results in Australia <i>Fong</i>	1014
Commentary: Surgeon preference reigns supreme <i>Lehenbauer</i>	1026
Commentary: This case is closed <i>Backer</i>	1028
Pulmonary Vein Stenosis: Management outcomes <i>Rosenblum & Alsoufi</i>	1029
Commentary: It takes a village: Trajectory of outcomes <i>Vanderlaan</i>	1037
Commentary: What we know & what to expect in the future <i>Hong</i>	1039
Pulmonary Valve: Stented pericardial prosthesis <i>Pragt & Van Melle</i>	1063
Commentary: All tissue valves fail <i>Lehenbauer</i>	1072
Commentary: PVR ... Is this the best we can do? <i>Quintessenza</i>	1074
MCS: Evolving understanding of TAH in infants & children <i>Woods</i>	1075
Commentary: Remove (a heart) or not, the question <i>Hope & Adachi</i>	1083
Commentary: Stepping stones to success <i>Thangappan & Morales</i>	1085

THORACIC

Lung Cancer: Nodal metastasis in ≤ 2 cm NSCLC <i>Pani & Singha</i>	1088
Commentary: Seek (the nodes) & you shall find <i>Hanna</i>	1097
Lung Cancer: Endosonography & nodes restaging: Review <i>Jiang & He</i>	1099
Commentary: Mediastinal restaging: Matter? <i>Menezes & Liberman</i>	1109
Lung Cancer: F-18 FDG uptake & pneumonia <i>Yamamichi & Shimada</i>	1111
Commentary: How to predict disaster? <i>Date</i>	1119
Lung: ET: Resection map for simulation <i>Tokuno & Chen-Yoshikawa</i>	1130
Commentary: Small technology step, giant leap for surgery <i>Weksler</i>	1139
Commentary: Seeking the grail? Choose wisely <i>D'Amico</i>	1141
Lung Transplantation: DVT screening after lung tx <i>Jorge & D'Cunha</i>	1142
Commentary: One more thing to complicate lung tx <i>Murthy</i>	1151
Commentary: Routine DVT screening after lung tx <i>McFadden</i>	1152
Commentary: DVT: Tip of the iceberg & long-term outcome <i>Lin</i>	1154