

## HISTOLOGICAL INVESTIGATION OF TESTIS IN INFERTILE MAN

### PART I. SOME CLINICAL PROBLEMS ON TESTICULAR BIOPSY

YUH MORITA

*Department of Urology, Nagoya University School of Medicine  
(Director: Associate Prof. Hideo Mitsuya)*

#### ABSTRACT

Based on histological investigation of the testes in 270 patients with functional infertility, in 13 patients with stenotic lesion and in 11 men with proven fertility, the following conclusions were obtained.

1) Testicular biopsy should be of first choice in the examination of male infertility. Epididymo-vaso-vesiculography to prove the patency of the seminal tracts is not always necessary. It should be done only on patients with testicular histology which can be expected the efficacy of treatment.

2) The size of biopsied specimen of the testis should be larger than half a pea, and open biopsy should be made in order to obtain a satisfactory size of specimen.

3) Bouin's solution is best for fixation of testicular tissue, and Carnoy's solution might be used, if Bouin's solution is not available. Zenker's solution and formol are not satisfactory for this purpose.

4) Biopsy is not necessary for both testes, and unilateral biopsy is sufficient to reveal the histological character of both testes, if no difference exists between the both testes by scrotal palpation.

5) In patients with sperm concentration much higher than  $20 \times 10^6$  per ml, information obtained by testicular biopsy is of little value.

6) In patients with testis smaller than thumb-head size, testicular biopsy shows severe damage, which discourages treatment.

7) Testicular injury due to biopsy procedure may lower the sperm concentration in patients with very low sperm counts. The effect may be irreversible.

#### INTRODUCTION

The value of testicular biopsy increases with understanding of testicular pathology. This procedure was once mainly used for the diagnosis and for treatment schedule of male infertility. Presently, the procedure can be used also to evaluate endocrinopathies and disorders of other organs which may manifest their effects on testicular function, such as adrenogenital syndrome, Cushing's disease, diabetes mellitus or periarteritis nodosa. In addition to

森 田 幽

Received for publication January 29, 1971.

them, by this method the effect of androgen blocking treatment in prostatic cancer can be better evaluated.

During the past five years, testicular biopsy was performed on 270 infertile males in our clinic. Before consideration of the pathology of male infertility, some clinical problems were discussed in this paper, which the author came across during clinical work. The problems under discussion are how to determine the indications of testicular biopsy, how better microscopic specimen can be prepared, how the surgical procedure depresses testicular function, whether X-ray study of the seminal tract is always necessary or not and certain other important matters.

#### MATERIALS, METHODS AND OBSERVATIONS

##### *I. Biopsy procedure*

In the present study, the open biopsy of testis was performed on 270 patients with the complaint of infertility, 214 with azoospermia and 56 with oligozoospermia, who had normal puberal development, normal virility and perfect general health. The age range of the patients varied from twenty-four to forty-two year. In all, no stenotic lesion of the seminal tract was proved by transvasal epididymo-vesiculography performed immediately after the testicular biopsy (In 227 patients with the azoospermia, 13 cases with stenotic lesion were diagnosed by the X-ray study). As normal controls, the testes of 11 men with known fertility were biopsied, aged twenty-eight to forty-six year, who were patients with hematospermia, prostatic sarcoma and hope for sterilization vasectomy, when they were performed intrascrotal surgical operations.

An open biopsy of testis was made by a modification of Charny's technique<sup>1)</sup>. Unilateral biopsy of the right testis was usually made, if there was seen no difference in size or consistency of both testes. At the beginning of this study, bilateral biopsy had been done. Similarity of the histological picture of the both testes, however, was found, when no difference was noticed between the both testes by scrotal palpation<sup>2)</sup>. If any difference was noted, bilateral biopsy has to be made.

The biopsied specimen was about the size of half a pea. All specimens were immediately fixed in Bouin's or Carnoy's solution for several hours, embedded in paraffin, sectioned 5 to 8  $\mu$  thick and stained conventionally with Hematoxylin-Eosin, Periodic-acid Schiff reaction and Heidenhain's technique.

In order to compare the effect of fixatives, Zenker's solution and formol were also used, in addition to Bouin's and Carnoy's solution.

*Case 1.* Man with proven fertility, aged 37, had prostatic sarcoma and the right testis was biopsied when transvasal vesiculography was performed to examine the tumor invasion into the seminal vesicles. A bean sized specimen

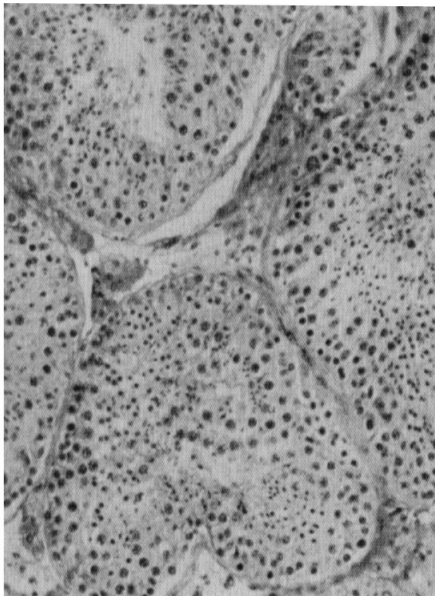


FIG. 1-a (Bouin)

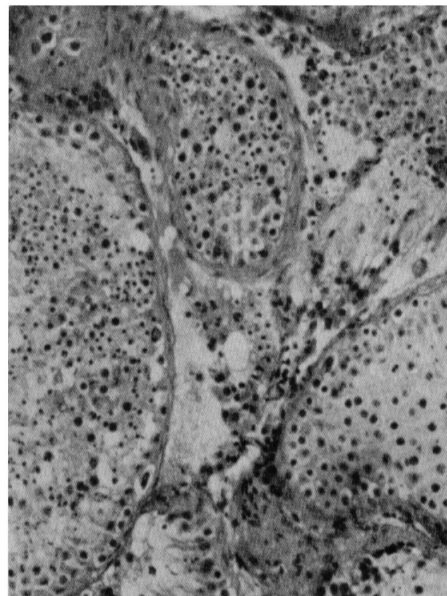


FIG. 1-b (Carnoy)

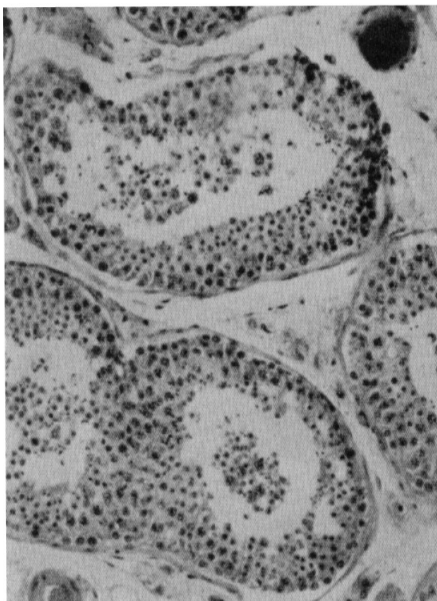


FIG. 1-c (Zenker)

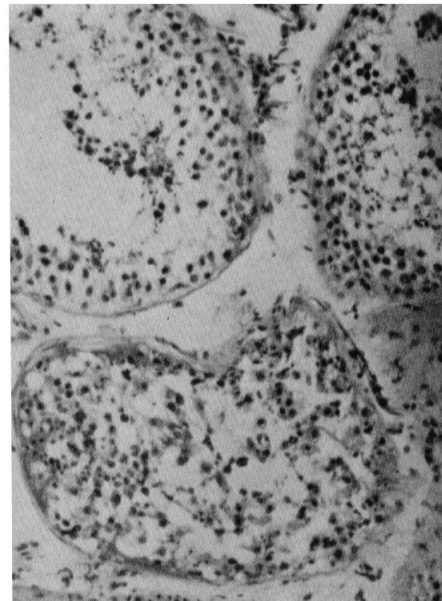


FIG. 1-d (Formol)

FIG. 1. Histological pictures of the normal testis ( $\times 100$ ), fixed in various fixatives. Note the superiority of fixation effect in Bouin's and Carnoy's solution.

was resected carefully from the middle part of the testis with a sharp blade. The biopsied sample was cut into four pieces and each fixed in Bouin's, Carnoy's and Zenker's solution and in formol, for 12 hours.

Figs. 1-a and 1-b are microphotographs of the normal testis fixed in Bouin's and Carnoy's solution.

Fig. 1-c is the picture of the same material fixed in Zenker's solution. The fixation effect is relatively satisfactory in the intratubular area, but not in the intertubular space, where the interstitial construction is lost entirely.

Fig. 1-d is the picture of the same material fixed in formol. Spermatogenesis is moderately reduced, though every tubule contains a fair amount of sperm cells. Deformity of the intratubular cells is seen, and the cell order is lost. Seminiferous tubules are spread far apart and are smaller in size. The tubular wall is wave-like in form. Lack of Leydig cells is also seen, due to improper fixation by formol.

*Case 2.* Man with azoospermia, aged 29, was biopsied in the same manner as Case 1. One half of the material was fixed in Bouin's solution and the other half in formol.

Fig. 2-a is the histological picture of the specimen fixed in Bouin's solution. Defect of germinal cells is seen in the majority of tubules, but a few tubules show almost normal spermatogenesis. The diameter of the damaged tubules

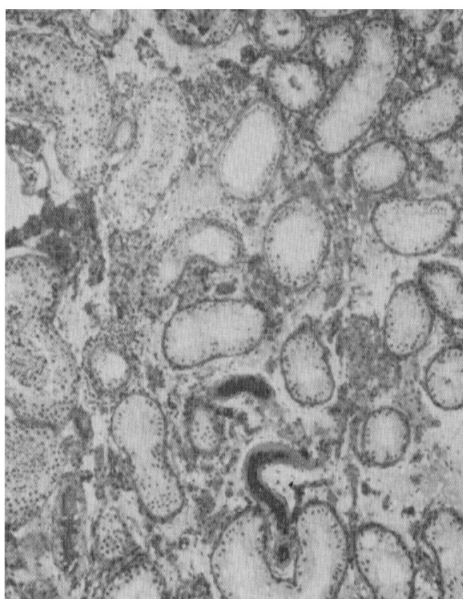


FIG. 2-a

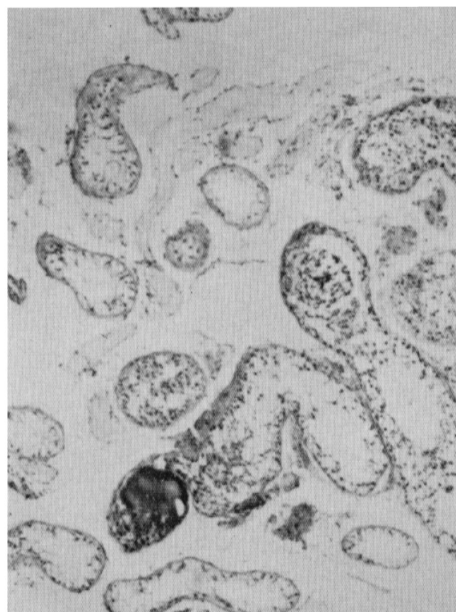


FIG. 2-b

FIG. 2. Testicular histology of patient with azoospermia ( $\times 40$ ). The specimen was fixed in Bouin's solution (2-a) and in formol (2-b).



is smaller and the tubular wall is thickened by hyaline degeneration. Clumping of Leydig cells is observed, but the cells near the tubules with normal appearance are not hyperplastic.

Fig. 2-b is the picture of the same material fixed in formol. Artefact caused by the fixative is not great at the damaged area, but is considerable at tubules with normal appearance.

### *II. Non-obstructive azoospermia with normal spermatogenesis*

Many patients without stenotic lesion of the seminal tracts were encountered, and the ejaculates showed no spermatozoa by repeated semen analyses, in spite of active sperm production in the seminiferous tubules or some slightly reduced spermatogenesis.

*Case 3.* Man with azoospermia, aged 42, was subjected to testicular biopsy and transvasal epididymo-vesiculography.

The testicular histology showed normal spermatogenesis (Fig. 3-a), and the epididymo-vesiculogram demonstrated no stenotic lesion of the seminal tracts though the seminal vesicles were slightly hypoplastic (Fig. 3-b). Sperm cells were never found by microscopic analyses of ejaculates, even in centrifuged specimens.

These cases presented a problem of "Where do the sperm cells, once produced intratubularly, disappear in the route of spermatozoa, from seminiferous tubules to ductus ejaculatorius?" In order to study this problem, a nylon cannule, 0.5 mm in I.D. and 1.0 mm in O.D., was inserted into both vasa towards the epididymal side, in six azoospermic patients with normal histological appearance and no stenotic lesion. Epididymo-vasal secretions were collected by the cannulation for 12 to 24 hours and examined microscopically. In the normal male numerous sperm cells could be obtained from the vasa in this manner. In the secretions of all six patients, sperm cells were never recovered though a few round cells and a moderate number of red blood cells were found.

### *III. Effect of unilateral biopsy on sperm concentration*

In order to see if sperm concentration is reduced by the testicular biopsy in oligozoospermia, semen analyses with a hemocytometer were repeated before and after biopsy. Semen specimens were collected from eight patients with oligozoospermia, with  $20 \times 10^6$  to  $2 \times 10^6$  per ml in sperm count. During the control period, semen analyses were made, twice or four times, before testicular biopsy. Semens were collected mostly by masturbation, and in a few with condom. No set period of continence was requested, since the author was primarily interested in what the donors were producing at their regular frequency of intercourse.

Follow-up semen analysis was begun when the scrotal wound was healed,

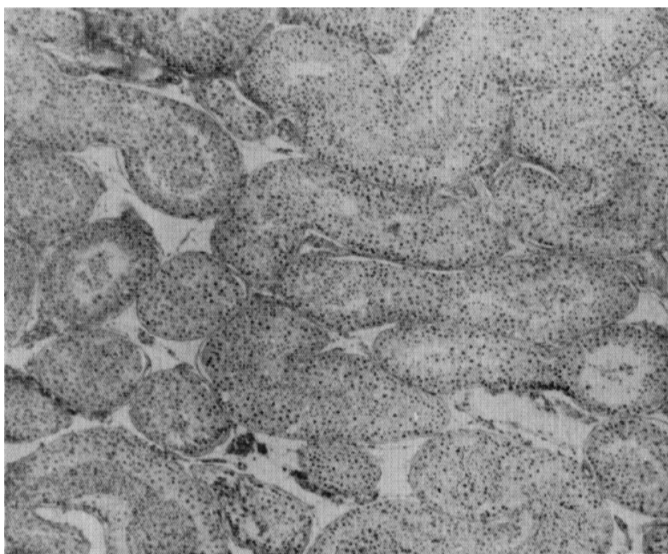


FIG. 3-a

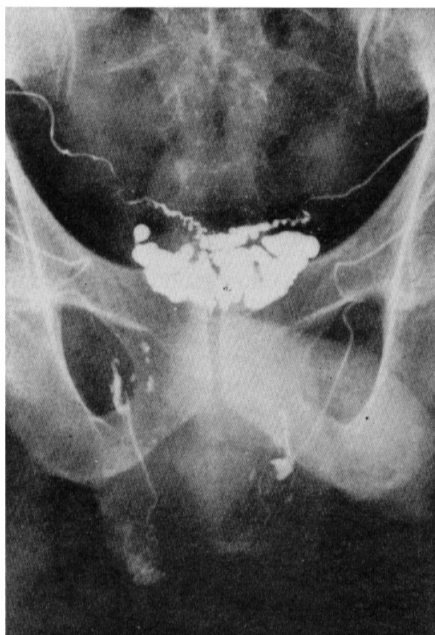

FIG. 3-b

FIG. 3. Histological picture ( $\times 40$ ) and epididymo-vesiculogram of patient with azoospermia. No germinal defect nor stenotic lesion are seen.

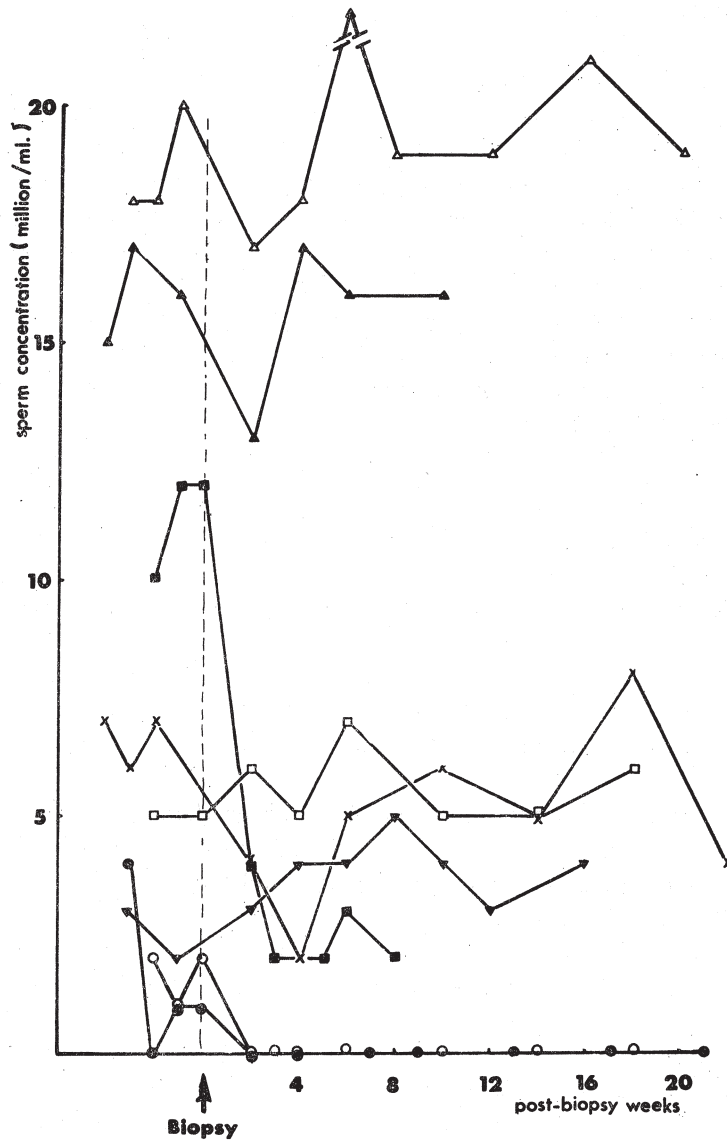


FIG. 4. Persistent sperm concentration for 20 weeks after unilateral biopsy of testis in patients with oligozoospermia. Note the drop in sperm concentration which returned to prebiopsy levels by 4 to 6 weeks, but in cases with very low sperm concentration the spermatozoa never recovered.

which took usually five to seven days after biopsy. Semens were obtained every seven or fourteen days of interval postoperatively. In eight patients with oligozoospermia, the alteration of sperm concentration before and after

unilateral testicular biopsy is shown in Fig. 4.

At an early phase after biopsy, six of the eight patients (75%) showed a depression of sperm concentration. Two showed recovery or improvement in their sperm counts. In the other four, the sperm concentration did not rise to the prebiopsy level. Two patients with very low sperm concentration lost the sperm cells in their ejaculates just after the testicular biopsy, at least till the twentieth post-biopsy week. Two of the eight patients (25%) did not demonstrate any decrease in sperm count. The ejaculate of this two patients showed relatively higher sperm concentration than the others.

Transvasal injection of contrast medium was made in all eight patients in order to examine the seminal tract, immediately after the testicular biopsy. Effect of contrast medium, vasal injury and X-ray should be taken into account in the consideration of the results.

#### DISCUSSION

##### *I. Technique*

##### *a) Surgical procedure*

Since Charny<sup>1)</sup>, it has been generally recognized that open biopsy is better than aspiration and punch methods. Traumatic damage of the testis is less than other methods, and postoperative hematoma is almost completely preventable by the open method. Further, observation and operation of intra-scrotal organs and X-ray study of the seminal tracts transvasally can be made, if necessary.

Size of the biopsied specimen should be larger than half a pea unless the testis is very small, since the soft and delicate tissue may be destroyed, especially lack of interstitium may occur, and the histological picture of very small testis shows occasionally regional variation<sup>2)</sup>. By punch method, greater injury is inevitable, if a satisfactory size of specimen is to be obtained. Usually punch method produces many artefacts due to the very small size and destruction of specimen.

The view against Charny's technique is that the general character of testis cannot be known by the small piece of tissue specimen. According to Kenneth and Walker, different histological pictures were shown in specimens from different parts of the testis, but Charny stated that the similarity of histological appearance was obtained in specimens collected from different parts of the testis.

##### *b) Fixation*

The details of the fixation technique have been described by Rowley and Heller<sup>3)</sup>. Usually, Bouin's, Carnoy's and Zenker's solution are used for testicular specimens. As Charny<sup>1)4)</sup> and Markewitz *et al.*<sup>5)</sup> recommended Bouin's solution, its superiority was also proved in the present work.



Mikawa<sup>9)</sup> stated that with Bouin's solution the tubular wall became loosely thick when compared with Carnoy's solution, but this was observed only when the duration of fixation was longer than over-night, in this experiment.

Zenker's solution made the specimen worse than Bouin's and Carnoy's solutions. Formol and alcohol were inadequate for histological investigations of the testis.

## *II. Whether unilateral or bilateral biopsy should be done?*

The question often arises whether both testes should be biopsied or not. It has been said that both testes present essentially similar histological pictures<sup>2)</sup>. At the beginning of this study, bilateral biopsy was carried out routinely, but we arrived at the concept mentioned above, and the unilateral method was adopted. Of course, it will be necessary to obtain specimens from both testes, if an appreciable difference in size or consistency of the testes exists, or in patient with stenotic lesion.

## *III. Effect of surgical procedure on sperm concentration in oligozoospermia*

Fall of sperm concentration due to testicular biopsy has been reported in experimental animals<sup>7) 8) 9)</sup>. Recently Goldon *et al.*<sup>10)</sup> reported on a similar effect in man. Rowley *et al.*<sup>11)</sup> reported that in 100 normal men with testicular biopsy, a drop of sperm count occurred in 39 persons and it took ten to eighteen weeks to return to the preoperative condition. According to Goldon *et al.*<sup>10)</sup>, in addition to traumatic orchitis, as an explanation of depression in sperm concentration, an antigen-antibody reaction may have been initiated by the surgical procedure resulting in destruction of spermatozoa and/or more immature cells in the testis.

In the present experiment it was also found in oligozoospermia that biopsy procedure caused considerable amount of damage to the low-functioning germinal epithelium. In two cases with much reduced sperm count, unilateral biopsy resulted in disappearance of sperm cells in the ejaculate, at least till twenty weeks after the biopsy. It can be said that the germinal damage in the right testis may effect the non-injured left testis, and the immunological explanation may be applied to this evidence.

## *IV. Indication*

Charny<sup>4)</sup> stated that testicular biopsy is not an indication for the patient with high sperm count, if the sperm count was higher, because the histological picture was normal or indistinguishable in biopsy of men with much higher sperm counts of  $50 \times 10^6$  to  $100 \times 10^6$  per ml. At our clinic the biopsy was indicated only in patients with sperm concentration below  $20 \times 10^6$  per ml, following repeated semen analyses. If the concentration is greater than  $20 \times 10^6$  per ml, testicular biopsy should not be performed, since no valuable finding is expected, even if the motility is poor or a high percentage of abnormal sperm is found by semen analysis.

Contrary to this, if the biopsy is carried out to find whether the testicular change is curable or not, little information is obtained from atrophic testis smaller than thumb-head, for the reason described in Part II<sup>14)</sup>.

Although the pathological changes of the testis in the majority of infertile men are seen in all areas of the testis diffusely, regional or nodular lesions are also seen occasionally. Tillinger<sup>12)</sup> reported that the error of histological diagnosis by biopsy was only 3%, but a small area of the testis, can not always represent all the pathological condition of the testis.

Based on the above considerations, testicular biopsy is necessary for the diagnosis of male infertility in the present day, as there is no better method available and its value will probably not fall.

#### *V. Necessity of X-ray study of seminal tract*

Though transvasal epididymo-vesiculography has been usually adopted together with open testicular biopsy at our clinic, it was reported that a depression of sperm concentration and motility occurred due to the injection of contrast medium into the seminal tracts and it caused an irreversible azoospermia in case of very low sperm concentration<sup>13)</sup>.

If it is necessary to prove the patency of the vas without the use of contrast medium, it can be determined by injection of diluted indigocarmine or marcurochrome into the vas and by inspection of the first urine and ejaculate passed by the patient after operation for blue or red coloration<sup>11)</sup>. This technique can not determine the side of stenosis, if it is unilateral.

The author believes that epididymo-vesiculography is not always necessary in the diagnosis of male infertility, for two reasons. First, in recent years, stenotic infertility has been very rare. In the past five years, of 227 cases of azoospermia seen at our clinic, only 13 cases (5.7%), showed stenotic lesions (Table 1). Though the testicular histology of the patients with acquired obstruction showed almost normal appearance, the patients with congenital anomaly in the seminal tracts showed testicular dysfunction, more or less. Second, even today we have no effective treatment for hypofunctional seminiferous tubules, at least for Sertoli-cell-only syndrome and complete hyaliniza-

TABLE 1. Stenotic Lesion in Seminal Tract was Revealed  
in Only 13 Cases out of 227 Azoospermic Patients  
Receiving Epididymo-Vesiculography

Congenital	Unilateral absence of vas	2
	Unilateral ectopia of seminal vesicle	1
Acquired	Tuberculosis	6
	Non-specific inflammation	1
	Post-vasectomy	3

tion of tubules. Patients with such highly damaged testis should be told to give up fertility, even when they have no obstruction in the male tracts. In such patients, who are not rare<sup>14)</sup>, X-ray examination is not needed, as the procedure is painful to the patient and requires longer operation time, when compared with biopsy-only surgery, and postoperative epididymitis may complicate.

If the histological picture encouraged the possibility of the treatment, the surgical procedure for X-ray study would be performed later.

#### IV. Non-obstructive azoospermia with normal spermatogenesis

To our surprise, we encountered some cases of unexplained azoospermia such as Case 3. Though it has been stated that azoospermia with normal histological picture must be associated with stenotic lesion elsewhere in the seminal tracts<sup>4)</sup>, the X-ray examination could not demonstrate any obstruction in these patients. Girgis *et al.*<sup>11)</sup> described "testiculo-epididymal obstruction of congenital origin" as shown by a normal testicular biopsy with spermatozoa and an empty though normal epididymal head. However, this diagnostic procedure can not reveal a state of the rete testis or the distal end of seminiferous tubules, if a destruction exists.

So, more attention should be paid to the phenomenon of *Non-obstructive azoospermia with normal testicular histology*. The pathological consideration of this is mentioned in Part II<sup>14)</sup>.

#### REFERENCES

- 1) Charny, C. W., The testicular biopsy: its value in male sterility, *J.A.M.A.*, **115**, 1429, 1940.
- 2) Nelson, W. O., Interpretation of testicular biopsy, *J.A.M.A.*, **151**, 451, 1953.
- 3) Rowley, M. J. and Heller, C. G., The testicular biopsy: surgical procedure, fixation and stain technique, *Fertil. Steril.*, **17**, 177, 1966.
- 4) Charny, C. W., Reflexion on testicular biopsy, *Fertil. Steril.*, **14**, 610, 1963.
- 5) Markewitz, M., Sommers, S. C., Veenema, R. J. and Butler, M. D., Testicular biopsy artifacts resulting from improper tissue processing, *J. Urol.*, **100**, 44, 1968.
- 6) Mikawa, I., Studies on the histology of the testes and the fraction of urinary 17-ketosteroids in infertile men, *Jap. J. Urol.*, **58**, 637, 1967 (in Japanese).
- 7) Freund, J., Lipton, M. M. and Thompson, G. E., Aspermatogenesis in the guinea pig induced by testicular tissue and adjuvant, *J. Exp. Med.*, **97**, 711, 1953.
- 8) Freund, J., Thompson, G. E. and Lipton, M. M., Aspermatogenesis, anaphylaxis and cutaneous sensitization induced in the guinea pig by homologous testicular extract, *J. Exp. Med.*, **101**, 591, 1954.
- 9) Furuta, H., Studies on male infertility, part II. studies on antigen-antibody reaction in the testis: histological change of the testis in active and reserved anaphylaxis, *Acta Urol. Jap.*, **15**, 360, 1969 (in Japanese).
- 10) Goldon, D. L., Barr, A. B., Herrigel, J. E. and Paulsen, C. A., Testicular biopsy in man; I. effect upon sperm concentration, *Fertil. Steril.*, **16**, 522, 1954.
- 11) Rowley, M. J., O'Keefe, K. B. and Heller, C. G., Decrease in sperm concentration due

- to testicular biopsy procedure in man, *J. Urol.*, **101**, 347, 1968.
- 12) Tillinger, K. G., Testicular morphology; a histopathological study with special reference to biopsy findings in hypogonadism with mainly endocrine disorders and in gynecomastia, *Acta Endocr. Suppl.*, **30**, 1, 1957.
  - 13) Segawa, A., Studies on secretory function of male sexual organs and their accessory glands, *Jap. J. Urol.*, **48**, 869, 1957 (in Japanese).
  - 14) Morita, Y., Histological investigation of testis in infertile man; Part II pathological problems, *Nagoya J. Med. Sci.*, **34**, 113, 1971.
-