

CASE REPORT

Nagoya J. Med. Sci. 78. 517 ~ 522, 2016
doi:10.18999/nagjms.78.4.517

Ruptured partially thrombosed anterior inferior cerebellar artery aneurysms: two case reports and review of literature

Fumiaki Kanamori¹, Teppei Kawabata², Shinsuke Muraoka², Takao Kojima¹,
Tadashi Watanabe¹, Norikazu Hatano³ and Yukio Seki¹

¹*Department of Neurosurgery, Japanese Red Cross Nagoya Daini Hospital, Nagoya, Japan*
²*Department of Neurosurgery, Nagoya University Graduate School of Medicine, Nagoya, Japan*
³*Medical Corporation Wakoukai, Kawashima Hospital, Nagoya, Japan*

ABSTRACT

Aneurysms arising from the distal anterior inferior cerebellar artery (AICA) are very rare. When the parent artery is an AICA–posterior inferior cerebellar artery (PICA) variant, occlusion of the artery, even distal to the meatal loop, leads to a significant area of cerebellar infarction. We report two cases of ruptured partially thrombosed distal AICA aneurysms. In both cases, the parent artery was an AICA–PICA variant. The aneurysms were clipped in one case and trapped following occipital artery (OA)–AICA anastomosis in another case. It is important to keep the OA as a donor artery for revascularization in the treatment of the AICA–PICA variant aneurysms, especially when the absence of intra-aneurysmal thrombus is not confirmed preoperatively.

Key Words: anterior inferior cerebellar artery, anastomosis, aneurysm, thrombosed, revascularization

This is an Open Access article distributed under the Creative Commons Attribution-NonCommercial-NoDerivatives 4.0 International License. To view the details of this license, please visit (<http://creativecommons.org/licenses/by-nc-nd/4.0/>).

INTRODUCTION

Anterior inferior cerebellar artery (AICA) aneurysms account for less than 1.0% of all intracranial aneurysms,^{1,2)} and distal AICA aneurysms are even more rare and constitute only about 0.1%.³⁻⁶⁾ Most AICA aneurysms are found after rupture,^{3,7)} and in such situations, it is not always easy to detect the presence of thrombus in the dome preoperatively from computed tomography (CT) and digital subtraction angiography (DSA) findings. In the presence of intra-aneurysmal thrombus, neck clipping of the aneurysm sometimes becomes difficult, necessitating an alternative treatment strategy such as trapping. We report two rare cases of ruptured partially thrombosed distal AICA–posterior inferior cerebellar artery (PICA) variant aneurysms, in one of which, preservation of the occipital artery (OA) as a donor artery for revascularization was helpful in avoiding ischemic complications.

Received: June 20, 2016; accepted: October 13, 2016

Corresponding author: Fumiaki Kanamori, MD

Department of Neurosurgery, Japanese Red Cross Nagoya Daini Hospital,
2-9 Myouken-cho, Showa-ku, Nagoya 466-8650, Japan

Tel: 052-832-1121, Fax: 052-832-1130, E-mail: shitetsu314@hotmail.co.jp

CASE REPORT

Case 1

A 40-year-old woman presented with occipital headache of sudden onset. Her Glasgow Coma Scale (GCS) score was E3V5M6 on admission. Head CT showed the presence of subarachnoid hemorrhage distributed dominantly in the posterior fossa and clot packing the fourth ventricle (Fig. 1A). DSA was performed, and left vertebral angiogram showed a hypoplastic PICA and a 2-mm saccular aneurysm on the distal portion of the left AICA, which was also supplying the distribution of the PICA (Fig. 1B). Under endotracheal general anesthesia, left lateral suboccipital craniotomy was performed following a hockey stick-shaped skin incision. After dural incision, the facial, vestibulocochlear, and lower cranial nerves were identified, and the aneurysm was exposed, which was partially thrombosed and much larger (10 mm in diameter) than noted on preoperative DSA. The neck of the aneurysm was clipped successfully, and there developed no ischemic lesion in the distribution of the parent artery (Figs. 1C, D, E). Postoperatively, she had laryngeal edema and hydrocephalus. After treatment for these complications, she was discharged without any neurological deficits.

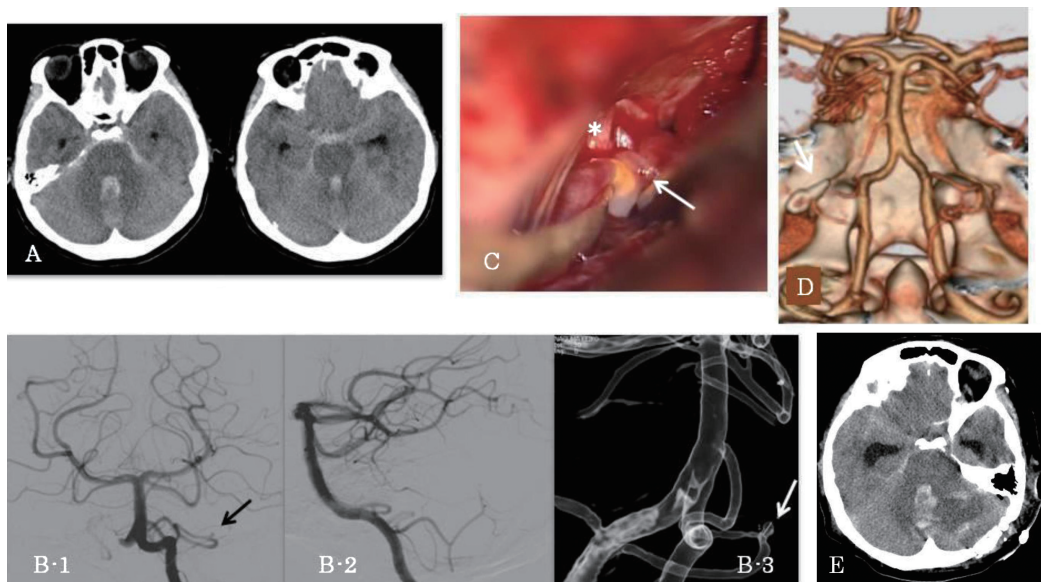


Fig. 1 Case 1

- A. Computed tomography scan (CT) on admission showing subarachnoid hemorrhage distributing dominantly in the posterior fossa associated with clot packing the fourth ventricle.
- B. Left vertebral angiograms: (1) anteroposterior view, (2) lateral view, and (3) right anterior oblique view demonstrating a 2-mm saccular aneurysm (arrow) on the distal portion of the left anterior inferior cerebellar artery–posterior inferior cerebellar artery variant.
- C. Intraoperative photograph showing the neck of the aneurysm (arrow).
*: left lower cranial nerves.
- D. Postoperative three-dimensional computed tomographic angiography demonstrating obliteration of the aneurysm (arrow) with a patent parent artery.
- E. Postoperative CT showing absence of ischemic lesion in the distribution of the parent artery.

Case 2

A 62-year-old man presented with occipital headache and nausea. On admission, his GCS score was E3V5M6, and he had mild right hemiparesis, mild right facial paralysis, right abducens nerve palsy, and dysarthria. Head CT showed the presence of diffuse subarachnoid hemorrhage (Fig. 2A). DSA was performed, and left vertebral angiogram showed a hypoplastic PICA and a 4-mm saccular aneurysm on the distal portion of the right AICA, which was also supplying the distribution of the PICA (Fig. 2B). Under endotracheal general anesthesia, right lateral suboccipital craniotomy was performed following a hockey stick-shaped skin incision. The aneurysm was partially thrombosed and much larger (13 mm in diameter) than noted on the preoperative DSA. Because of thrombus, the neck of the aneurysm was hard and not amenable to clipping. Therefore, an OA–AICA anastomosis was performed, and the aneurysm was trapped (Fig. 2C). Postoperative magnetic resonance imaging demonstrated the thrombosed aneurysm clearly in the right cerebellomedullary cistern and absence of ischemic lesions in the cerebellum (Fig. 2D). Postoperative DSA showed good patency of the bypass (Fig. 2E). In the subacute period, his right hemiparesis showed some improvement and his right abducens nerve palsy remained unchanged, so he was transferred to a rehabilitation hospital with his modified Rankin Scale score of 3.

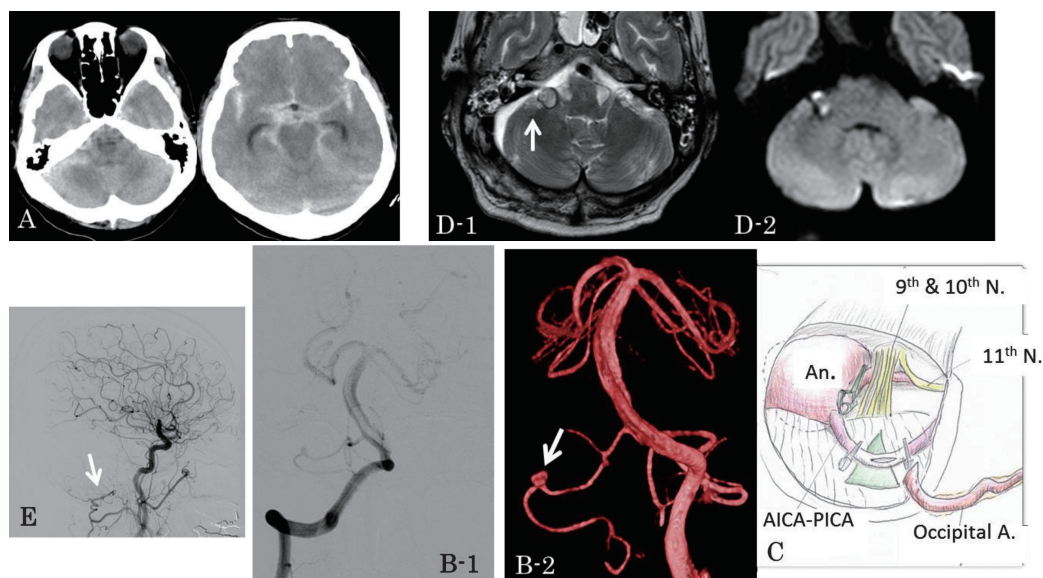


Fig. 2 Case 2

- A. Computed tomography scan on admission showing diffuse subarachnoid hemorrhage.
- B. (1) Right vertebral angiogram, anteroposterior view, showing that the right anterior inferior cerebellar artery (AICA) is an AICA–posterior inferior cerebellar artery variant; (2) left vertebral angiogram, anteroposterior view, demonstrating a 4-mm saccular aneurysm (arrow) on the distal portion of the right AICA.
- C. Intraoperative schema showing anatomical location and appearance of the aneurysm; the aneurysm was partially thrombosed and its diameter was about 13 mm. Occipital artery (OA)–AICA anastomosis was performed, and the aneurysm was trapped.
- D. Postoperative magnetic resonance images; (1) T2-weighted image showing the real size of the thrombosed aneurysm (arrow). (2) Diffusion-weighted image showing absence of ischemic lesion.
- E. Postoperative right carotid angiogram showing patency of the OA–AICA anastomosis.

DISCUSSION

AICA aneurysms account for less than 1.0% of all intracranial aneurysms.^{1,2)} Most AICA aneurysms are located at the proximal portion, and distal AICA aneurysms are very rare, constituting only about 0.1%.³⁻⁶⁾ To the best of our knowledge, only a few partially thrombosed distal AICA aneurysms have been reported in the English literature (Table 1).^{4,7-13)} Most AICA aneurysms are found after rupture.^{3,7)} In cases of non-ruptured AICA aneurysms, patients present with headache, facial hypesthesia, trigeminal neuralgia, hearing disorder, or facial paralysis.^{7,9,11)} and an intrameatal aneurysm may be diagnosed as a tumor involving the internal auditory canal preoperatively.^{7,9)}

Table 1 Reported cases of partially thrombosed anterior inferior cerebellar artery aneurysms

No.	Author/year	Age/ sex	Presentation	Aneurysm				Treatment	Sequela
				Hemorrhage	Location	Size	Type		
1	Cantore, 1982	35/M	vertigo, facial pain & hypesthesia, facial paralysis, hearing disorder, nystagmus	non-ruptured	distal	giant	saccular	trapping & thrombectomy	incomplete facial paralysis
2	Zager, 1991	25/F	headache, facial numbness	ruptured	distal	20 mm	fusiform	trapping & aneurysm excision	facial numbness
3	Pritz, 1993	33/M	headache	non-ruptured	proximal	giant	calcified mass	decompression	cricopharyngeal achalasia
4	Ildan, 1996	43/F	trigeminal neuralgia, headache, drowsiness	ruptured	distal	15 mm	saccular	clipping & aneurysm excision	none
5	Sarkar, 2004	60/M	headache, facial paralysis, hearing loss, nystagmus	non-ruptured	distal	10 mm	fusiform	trapping & thrombectomy	facial paralysis, hearing disorder, ataxia, nystagmus
6	Bambakidis, 2009	58/F	headache, dizziness	non-ruptured	proximal	10 mm	saccular	clipping	none
7	Oyama, 2010	65/F	nausea, occipital headache, respiratory arrest	ruptured	distal	large	fusiform	trapping with OA–AICA anastomosis & thrombectomy	dysphagia, hemiplegia
8	Pasler, 2011	22/M	headache, hearing loss, facial paralysis	non-ruptured	distal	N.A.	saccular	aneurysm excision with end to end anastomosis	hearing loss, headache
9	Present Case 1	40/F	headache	ruptured	distal	10 mm	saccular	clipping	none
10	Present Case 2	62/M	headache, hemiparesis, facial paralysis, dysarthria	ruptured	distal	13 mm	saccular	trapping with OA–AICA anastomosis	mild hemiparesis, diplopia

AICA: anterior inferior cerebellar artery, N.A.: not available, OA: occipital artery

AICA aneurysms have been treated by microsurgery, endovascular therapy, or a combination of the two. Occlusion of the AICA may lead to ataxia, nystagmus, dysarthria, trigeminal sensory impairment, lateral gaze palsy, facial palsy, hearing loss, and motor weakness.¹⁴⁻¹⁹⁾ On the other hand, some authors have reported that therapeutic occlusion of the AICA resulted in no deficits.²⁰⁻²⁶⁾ Factors affecting these neurological outcomes include the site of parent artery occlusion, the volume of blood supply from the collateral circulation, and involvement of nerve-related branches such as the labyrinthine artery, the recurrent perforating arteries, and the subarcuate artery. For example, if the lesion is located distal to the meatal loop or a supplementary AICA is present,^{23,27)} hearing preservation may be possible after occlusion of the affected site. It has been reported that the size of the infarcted area due to AICA occlusion is inversely related to the sizes of the PICA and superior cerebellar artery.²⁸⁾ In both of our cases, ruptured aneurysms were located in the distal portion of the AICA–PICA variant, suggesting preservation of the parent artery was necessary to avoid serious cerebellar infarction.

As in Case 2, it is sometimes difficult to place a clip appropriately across the neck of a partially thrombosed aneurysm. In such a case, trapping of the aneurysm with an OA–AICA anastomosis may be a safer procedure than the more challenging neck clipping after thrombectomy. Trapping of AICA aneurysms or dissection in combination with OA–AICA anastomosis has been reported by several authors.^{8,29-31)} Another option for revascularization of the AICA is aneurysm excision with end-to-end anastomosis of the AICA.⁷⁾ Depending on the situation, the former may be easier than the latter because of a more shallow site of anastomosis. We also think that building a good anastomosis may have an advantage to maintain enough distal tissue circulation in case of vasospasm in the proximal portion of the parent artery. Neurological deficits at the time of discharge in Case 2 were mostly related to the first impact of hemorrhage.

In conclusion, when treating AICA–PICA variant aneurysms surgically, it is safer to preserve enough length of the OA in a hockey stick-shaped musculocutaneous flap as a donor for OA–AICA anastomosis in case of partially thrombosed aneurysms that necessitate trapping for obliteration.

CONFLICTS OF INTEREST DISCLOSURE

The authors have no personal, financial, or institutional interest in any of the drugs, materials, or devices presented in this article. All authors who are members of the Japan Neurosurgical Society (JNS) have registered online using the self-reported COI disclosure statement forms through the website for JNS members.

REFERENCES

- 1) Locksley HB, Sahs AL, Knowler L. Report on the cooperative study of intracranial aneurysms and subarachnoid hemorrhage. Section II. General survey of cases in the central registry and characteristics of the sample population. *J Neurosurg*, 1966; 24: 922–932.
- 2) Peerless SJ, Hernesniemi JA, Gutman FB, Drake CG. Early surgery for ruptured vertebrobasilar aneurysms. *J Neurosurg*, 1994; 80: 643–649.
- 3) Gonzalez LF, Alexander MJ, McDougall CG, Spetzler RF. Anteroinferior cerebellar artery aneurysms: surgical approaches and outcomes – a review of 34 cases. *Neurosurgery*, 2004; 55: 1025–1035.
- 4) Ildan F, Gocer AI, Bagdatoglu H, Uzuneyupoglu Z, Tuna M, Cetinalp E. Isolated trigeminal neuralgia secondary to distal anterior inferior cerebellar artery aneurysm. *Neurosurg Rev*, 1996; 19: 43–46.
- 5) Mizushima H, Kobayashi N, Yoshiharu S, Kazuo H, Dohi K, Sasaki K, *et al.* Aneurysm of the distal anterior inferior cerebellar artery at the medial branch: a case report and review of the literature. *Surg Neurol*, 1999; 52: 137–142.
- 6) Suzuki J, Hori S, Sakurai Y. Intracranial aneurysms in the neurosurgical clinics in Japan. *J Neurosurg*, 1971; 35: 34–39.
- 7) Pasler D, Baldauf J, Runge U, Schroeder HW. Intrameatal thrombosed anterior inferior cerebellar artery aneurysm mimicking a vestibular schwannoma. *J Neurosurg*, 2011; 114: 1057–1060.
- 8) Oyama H, Kito A, Maki H, Hattori K, Tanahashi K. Compression of the medulla oblongata and acute respiratory failure caused by rupture of a thrombosed large aneurysm of the anterior inferior cerebellar artery. *Neurol Med Chir (Tokyo)*, 2010; 50: 571–573.
- 9) Sarkar A, Link MJ. Distal anterior inferior cerebellar artery aneurysm masquerading as a cerebellopontine angle tumor: case report and review of literature. *Skull Base*, 2004; 14: 101–106; discussion 106–107.
- 10) Zager EL. Isolated trigeminal sensory loss secondary to a distal anterior inferior cerebellar artery aneurysm: case report. *Neurosurgery*, 1991; 28: 288–291.
- 11) Cantore GP, Ciappetta P, Vagnozzi R, Bozzao L. Giant aneurysm of the anterior inferior cerebellar artery simulating a cerebellopontine angle tumor. *Surg Neurol*, 1982; 18: 76–78.
- 12) Pritz MB. Aneurysms of the anterior inferior cerebellar artery. *Acta Neurochir (Wien)*, 1993; 120: 12–19.
- 13) Bambakidis NC, Manjila S, Dashti S, Tarr R, Megerian CA. Management of anterior inferior cerebellar

- artery aneurysms: an illustrative case and review of literature. *Neurosurg Focus*, 2009; 26: E6.
- 14) Ishii D, Takechi A, Shinagawa K, Sogabe T. Endovascular treatment for ruptured distal anterior inferior cerebellar artery aneurysm -case report. *Neurol Med Chir (Tokyo)*, 2010; 50: 396–399.
 - 15) Saito R, Tominaga T, Ezura M, Shimizu H, Yoshimoto T. Distal anterior inferior cerebellar artery aneurysms: report of three cases and literature review. *No Shinkei Geka*, 2001(in Japanese); 29: 709–714.
 - 16) Santillan A, Gobin YP, Patsalides A, Riina HA, Rosengart A, Stieg PE. Endovascular management of distal anterior inferior cerebellar artery aneurysms: Report of two cases and review of the literature. *Surg Neurol Int*, 2011; 2: 95.
 - 17) Takemoto Y, Kawano T, Nishi T, Kuratsu J. Formation of a pseudoaneurysm in the chronic phase at the site of a ruptured dissecting anterior inferior cerebellar artery aneurysm. *Acta Neurochir (Wien)*, 2015; 157: 1045–1047.
 - 18) Yokoyama S, Kadota K, Asakura T, Kawazoe K. Aneurysm of the distal anterior inferior cerebellar artery – case report. *Neurol Med Chir (Tokyo)*, 1995; 35: 587–590.
 - 19) Amarenco P, Hauw JJ. Cerebellar infarction in the territory of the anterior and inferior cerebellar artery. A clinicopathological study of 20 cases. *Brain*, 1990; 113: 139–55.
 - 20) Kang HS, Roh HG, Han MH, Koh YC. Successful endovascular occlusion of a ruptured distal anterior inferior cerebellar artery aneurysm of the caudal trunk: case report. *Interv Neuroradiol*, 2007; 13: 271–276.
 - 21) Lv X, Li Y, Liu A, Zhang J, Wu Z. Parent artery occlusion for peripheral anterior inferior cerebellar artery aneurysm. A case report and review of the literature. *Neuroradiol J*, 2008; 21: 261–265.
 - 22) Suzuki K, Meguro K, Wada M, Fujita K, Nose T. Embolization of a ruptured aneurysm of the distal anterior inferior cerebellar artery: case report and review of the literature. *Surg Neurol*, 1999; 51: 509–512.
 - 23) Takeuchi S, Takasato Y, Masaoka H, Hayakawa T, Otani N, Yoshino Y, *et al.* [Trapping of ruptured dissecting aneurysm of distal anterior inferior cerebellar artery – case report]. *Brain Nerve*, 2009; 61: 203–207.
 - 24) Yamaguchi S, Kato T, Takeda M, Ikeda H, Kitamura K. Ruptured distal anterior inferior cerebellar artery aneurysm following stereotactic irradiation for vestibular schwannoma: case report. *Neurol Med Chir (Tokyo)*, 2009; 49: 202–205.
 - 25) Zager EL, Shaver EG, Hurst RW, Flamm ES. Distal anterior inferior cerebellar artery aneurysms. Report of four cases. *J Neurosurg*, 2002; 97: 692–696.
 - 26) Mascitelli JR, McNeill IT, Berenstein A, DeMattia J, Fifi JT. Ruptured distal AICA pseudoaneurysm presenting years after vestibular schwannoma resection and radiation. *BMJ Case Rep*, 2015; 6: 10.
 - 27) Okumura Y, Sakaki T, Hirabayashi H, Shimomura T. Intrameatal aneurysm successfully treated by meatal loop trapping – case report. *Neurol Med Chir (Tokyo)*, 1999; 39: 161–164.
 - 28) Rhoton AL. Rhoton's Cranial Anatomy and Surgical Approaches. pp 461–500, 2003, Lippincott Williams & Wilkins, Schaumburg, Illinois,.
 - 29) Fujimura M, Inoue T, Shimizu H, Tominaga T. Occipital artery-anterior inferior cerebellar artery bypass with microsurgical trapping for exclusively intra-meatal anterior inferior cerebellar artery aneurysm manifesting as subarachnoid hemorrhage. Case report. *Neurol Med Chir (Tokyo)*, 2012; 52: 435–438.
 - 30) Fukushima S, Hirohata M, Okamoto Y, Yamashita S, Ishida S, Shigemori M. Anterior inferior cerebellar artery dissecting aneurysm in a juvenile: case report. *Neurol Med Chir (Tokyo)*, 2009; 49: 81–84.
 - 31) Gi H, Inoha S, Uno J, Ikai Y, Koga H, Yamaguchi S, *et al.* [Four cases of direct surgery for anterior inferior cerebellar artery aneurysms]. *No Shinkei Geka*, 2007; 35: 571–578.