

HIGH OSMOLARITY EFFECT OF INTRAVITREAL PLASMIN ENZYME ON RABBIT RETINA

TETSU ASAMI¹, MD, PhD; SHU KACHI¹, MD, PhD; USAMA ALI MOHAMED^{1,2}, MD; YASUKI ITO¹, MD, PhD; and HIROKO TERASAKI¹, MD, PhD

¹*Department of Ophthalmology, Nagoya University Graduate School of Medicine, Nagoya, Japan*

²*Department of Ophthalmology, Sohag University, Faculty of Medicine, Sohag, Egypt*

ABSTRACT

We conducted a study of the effect of intravitreal plasmin on retinal thickness in rabbits. Forty rabbit eyes were injected with 0.4, 1, 2, and 5 IU of plasmin (8 eyes/group). The same volume of BSS-plus[®] was injected in control eyes. Four eyes in each group underwent vitrectomy 60 minutes after the injections. The retinal thickness was measured in optical coherence tomographic (OCT) images before, 30 minutes, and 1 week after the injection. To study the effect of hyperosmolarity, 4 eyes received an injection of mannitol solution whose osmolarity was the same as the plasmin solutions. Thirty minutes after the plasmin injection, 4 eyes developed a serous retinal detachment (SRD). The mean retinal thickness including SRD was increased at 30 minutes in a dose-dependent way. The increase in eyes with 5 IU of plasmin was significantly greater than that in eyes with BSS-Plus[®] or 0.4 IU of plasmin ($P = 0.0266$, $P = 0.0371$, respectively). One week after the injection, SRD disappeared, and the mean retinal thickness decreased. The eyes injected with mannitol, the same osmolarity of 1, 2, 5 IU of plasmin, developed SRD at 30 minutes, and it disappeared after 1 week in all eyes. The results of this study demonstrated that an intravitreal injection of plasmin increases the retinal thickness in a dose-dependent way in rabbit eyes. The results with mannitol suggest that the increase in retinal thickness following plasmin is most likely caused by the hyperosmolarity of plasmin solution.

Key Words: plasmin, retinal thickness, serous retinal detachment, high osmolarity, posterior vitreous detachment

INTRODUCTION

Plasmin, a serine protease mediating fibrinolytic enzyme, hydrolyzes glycoproteins such as laminin and fibronectin.¹⁾ Both of these proteins play an important role in attaching the vitreous to the internal limiting membrane (ILM). The separation of the vitreous from the retina by cleaving the linkages at the vitreoretinal interface enzymatically may reduce the risk of intraoperative complications, e.g., retinal breaks, retinal detachment, or retinal nerve fiber damage.²⁻⁴⁾

Since Verstraeten *et al.*⁵⁾ demonstrated that plasmin could be a useful biochemical adjunct to mechanical vitrectomy in rabbit eyes, the facilitating effects of plasmin on posterior vitreous detachment (PVD) have been demonstrated by light and electron microscopy in rabbits,⁶⁾ pigs,⁷⁾

Received: December 11, 2014; accepted: January 14, 2015

Corresponding author: Tetsu Asami, MD

Department of Ophthalmology, Nagoya University Graduate School of Medicine, 65 Tsuruma-cho, Showa-ku, Nagoya 466-8550, Japan

E-mail asami@med.nagoya-u.ac.jp

and postmortem human eyes.⁸⁻¹⁰ The effects of plasmin have also been studied clinically.¹¹⁻¹⁵

One of the adverse effects of intravitreal plasmin is the transient decrease in the electroretinogram amplitudes. This decrease was suggested to be due to the osmotic effect of plasmin,⁵ because Marmor¹⁶ had shown that an intravitreal injection of hyperosmotic solutions can cause a large retinal detachment and a permanent degeneration of the retina. Therefore, the effect of osmolarity should be considered when the adverse effects of plasmin are examined.

To date, the effects of plasmin on the morphology of the retina of living animals have not been well described. Thus, the purpose of this study was to determine the morphological changes of the vitreoretinal interface and retinal thickness by optical coherence tomography (OCT) after an intravitreal injection of plasmin. To control for the effect of osmolarity, hyperosmotic solutions were also injected intravitreally, and the retina was examined in the same way.

MATERIALS AND METHODS

Young Dutch rabbits weighting approximately 2.5 kg were handled in accordance with the Principles of Laboratory Animal Care of the National Institutes of Health. The experimental protocol used was approved by the Animal Use Committee of Nagoya University School of Medicine.

The rabbits were anesthetized with an intramuscular injection of ketamine hydrochloride (10 mg/kg loading dose, then 10 mg/kg per hour) and 1 mg/kg xylazine. The pupil was dilated with a combination of 0.5% phenylephrine hydrochloride and 0.5% tropicamide.

The animals were randomly assigned to 1 of 2 groups. Group 1 included 40 eyes. Eight of these 40 eyes received an injection of 0.1 ml of balanced salt solution (BSS-plus[®]; Alcon, Fort Worth, TX). The other 32 eyes received a midvitreal injection of 0.4, 1, 2, or 5 IU of human plasmin (CalBiochem Corp, La Jolla, CA). There were 8 eyes at each dose. The vials of plasmin had been stored at -20°C until use, and the plasmin was reconstituted in 0.1 ml of sterile BSS-plus[®] at room temperature to the final concentrations.⁵ Sixty minutes after the injections, 4 eyes at each concentration underwent core vitrectomy without lensectomy or mechanical attempts to induce PVD.

Group 2 included 4 eyes. Each received a midvitreal injection of 0.1 ml of hyperosmotic solution. To make the hyperosmotic solutions, D(-)-mannitol (Sigma-Aldrich Japan Co., Inc., Tokyo, Japan) powder was dissolved in sterile distilled water to a concentration of 68.0, 87.0, 117.5 and 203.0 mg/ml. These concentrations were measured to be 390, 500, 690, and 1250 mOsm, respectively, which were equivalent to those of plasmin solutions at concentrations of 0.4, 1, 2 and 5 IU/0.1 ml, respectively.

OCT examinations

Cross-sectional horizontal images of the retina were obtained by the Humphrey OCT instrument (Humphrey Instruments, San Leandro, Calif) at 3 disc diameters from the inferior margin of the optic disc. The scan lengths were 2.8 mm in Group 1 and 11.0 mm in Group 2. The scans were obtained before and 30 minutes and 1 week after the injection of plasmin in eyes with and without vitrectomy in Group 1, and before and 30 minutes and 1 week after the injection of mannitol solutions in Group 2.

Quantitative analysis

The retinal thickness was selected to be the distance between the surface of retina to the anterior surface of high reflectivity layer which was assumed to be the retinal pigment epithelium

(RPE). When a retinal detachment was present, the retinal thickness was measured as the distance between the surface of the retina and the anterior border of the RPE and included the subretinal fluid space.

Statistical analyses

The analyses were performed using the Statview (Abacus Concepts Inc, Berkeley, Calif) statistical analysis package. All data are expressed as the means \pm standard error of the means (SEM). The mean changes in retinal thickness were compared between each group using ANOVA with the Fisher protected least significant difference for the post hoc test. Values of $P < 0.05$ were considered significant.

RESULTS

Representative OCT images of eyes in Group 1 with and without vitrectomy are shown in Figures 1a and 1b, respectively. Thirty minutes after plasmin injection of 0.4 IU (1 eye), 2 IU (1 eye), and 5 IU (2 eyes), 4 of the 32 eyes developed PVD. The number of eyes at each dose that had PVD increased to 4 (0.4 IU), 2 (1 IU), 4 (2 IU), and 3 (5 IU) eyes one week later. None of the eyes injected with BSS-plus[®] (Table) developed PVD.

Four eyes that received ≥ 1 IU of plasmin developed a retinal detachment (RD). However, the RD disappeared in all eyes after 1 week regardless of whether vitrectomy had been performed (Figure 1).

The mean changes in the retinal thickness 30 minutes after the plasmin injection in Group 1 ($n = 8$) are shown in Figure 2A. The changes in the mean retinal thickness in eyes with BSS-plus[®], 0.4 IU, 1 IU, 2 IU, and 5 IU were; $-3 \pm 3 \mu\text{m}$, $3 \pm 5 \mu\text{m}$, $29 \pm 20 \mu\text{m}$, $30 \pm 29 \mu\text{m}$, and $93 \pm 55 \mu\text{m}$, respectively. The mean retinal thickness in eyes with 5 IU of plasmin was significantly thicker than that in eyes with BSS-plus[®] and 0.4 IU of plasmin ($P = 0.0266$, $P = 0.0371$, respectively).

Without vitrectomy, the mean retinal thickness changes in eyes with BSS-plus[®], 0.4 IU, 1 IU, 2 IU, and 5 IU of plasmin one week after the injection ($n = 4$) were; $-7 \pm 4 \mu\text{m}$, $14 \pm 3 \mu\text{m}$, $19 \pm 8 \mu\text{m}$, $11 \pm 4 \mu\text{m}$, and $15 \pm 2 \mu\text{m}$, respectively (Figure 2B). The mean retinal thickness changes one week after the plasmin injection in eyes injected with 0.4 IU, 1 IU, 2 IU, and 5 IU were significantly thicker than that in eyes with BSS-plus[®] ($P = 0.0127$, $P = 0.0021$, $P = 0.0313$, $P = 0.0079$, respectively).

With vitrectomy, the mean retinal thickness changes in eyes with BSS-plus[®], 0.4 IU, 1 IU, 2 IU, and 5 IU of plasmin one week after injection ($n = 4$) were; $6 \pm 12 \mu\text{m}$, $25 \pm 2 \mu\text{m}$, $12 \pm 7 \mu\text{m}$, $18 \pm 5 \mu\text{m}$, and $31 \pm 5 \mu\text{m}$, respectively (Figure 2C). The mean retinal thickness change in eyes with 5 IU was significantly thicker than those with BSS-plus and 1 IU of plasmin ($P = 0.0058$, $P = 0.0187$, respectively).

The effects of mannitol solution on the rabbit retina are shown in Figures 3 and 4. Thirty minutes after the mannitol injection, RD was detected in eyes receiving an injection of the 500 mOsm, 690 mOsm, and 1250 mOsm solutions. These osmolarities were the same as that with 1 IU, 2 IU, and 5 IU of plasmin solution, respectively. The RD disappeared after 1 week in all eyes.

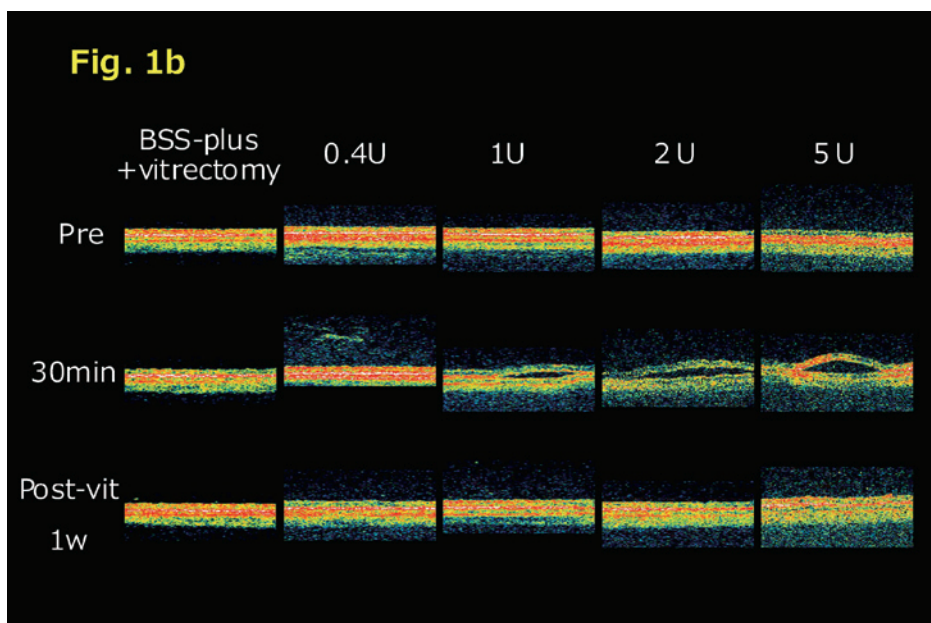
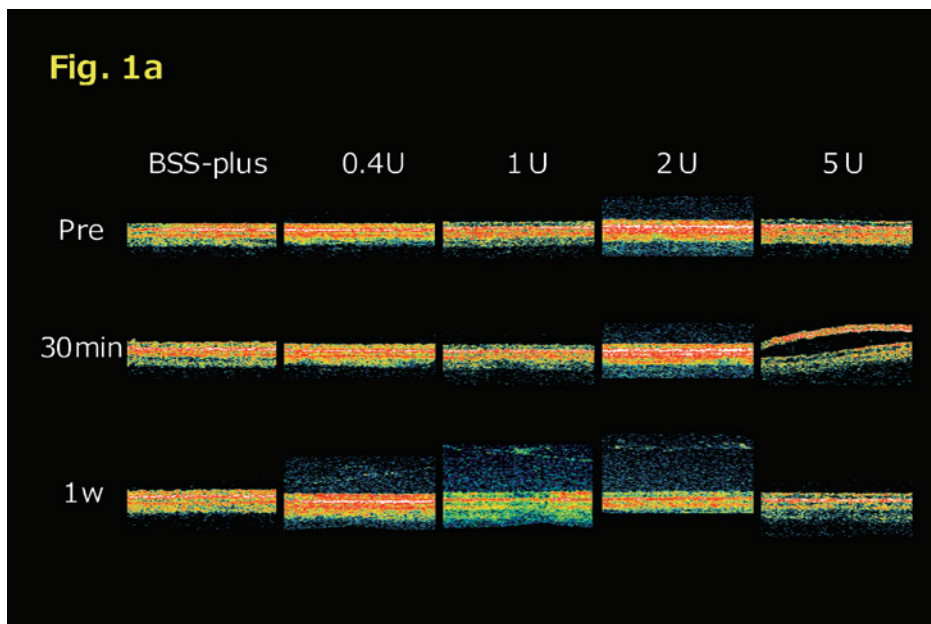


Fig. 1 Optical coherence tomographic images after plasmin injection

- Representative optical coherence tomographic images of the retina with only plasmin injection. Scan length was 2.83 mm. The images of eyes 1 week after injections of 0.4, 1, and 2 IU of plasmin show a posterior vitreous detachment. In eye with 5 IU of plasmin, a serous retinal detachment can be seen after 30 minutes. The eye at 1 week after plasmin does not show a retinal detachment.
- Representative optical coherence tomographic images of the retina after plasmin injection followed by vitrectomy. Thirty minutes after 0.4 IU of plasmin injection, a posterior vitreous detachment is observed. A serous retinal detachment can be seen in eyes with injections of 1, 2, and 5 IU of plasmin. A retinal detachment was not seen in all eyes after 1 week.

HIGH OSMOLARITY EFFECT OF PLASMIN

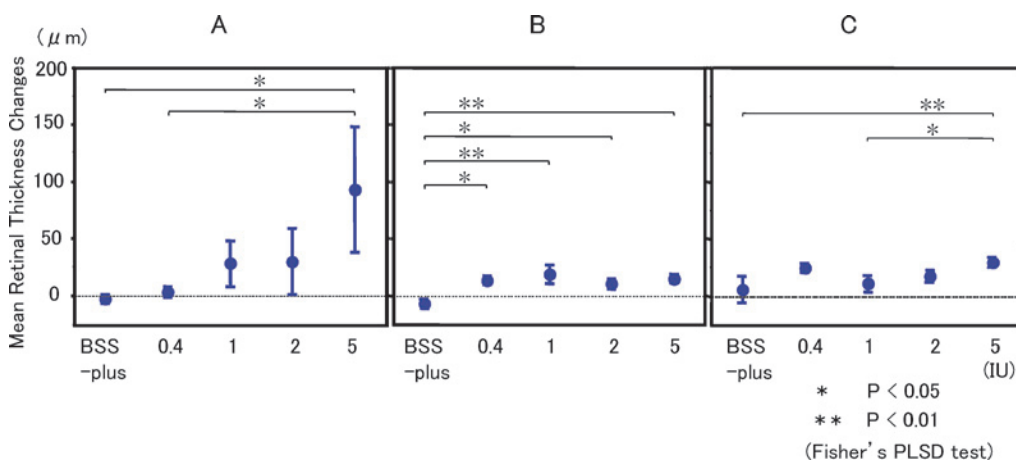


Fig. 2 Mean retinal thickness changes after plasmin injection

Mean retinal thickness (retinal pigment epithelium to internal limiting membrane) after plasmin injection.

- Mean retinal thickness changes 30 minutes after plasmin injection ($n = 8$). The mean retinal thickness change in eyes with 5 IU of plasmin was statistically larger than those in eyes with BSS-plus[®] and 0.4 IU ($*P < 0.05$; Fisher's PLSD for post hoc test).
- Mean retinal thickness changes 1 week after the plasmin injection alone ($n=4$). The mean retinal thickness changes in eyes injected with 0.4 IU, 1 IU, 2 IU, and 5 IU were significantly thicker than that in eyes with BSS-plus[®] ($*P < 0.05$, $**P < 0.01$; Fisher's PLSD for post hoc test).
- Mean retinal thickness changes one week after plasmin injection followed by vitrectomy ($n = 4$). The mean retinal thickness change in eyes with 5IU was significantly thicker than those with BSS-plus and 1IU of plasmin ($*P < 0.05$, $**P < 0.01$; Fisher's PLSD for post hoc test).

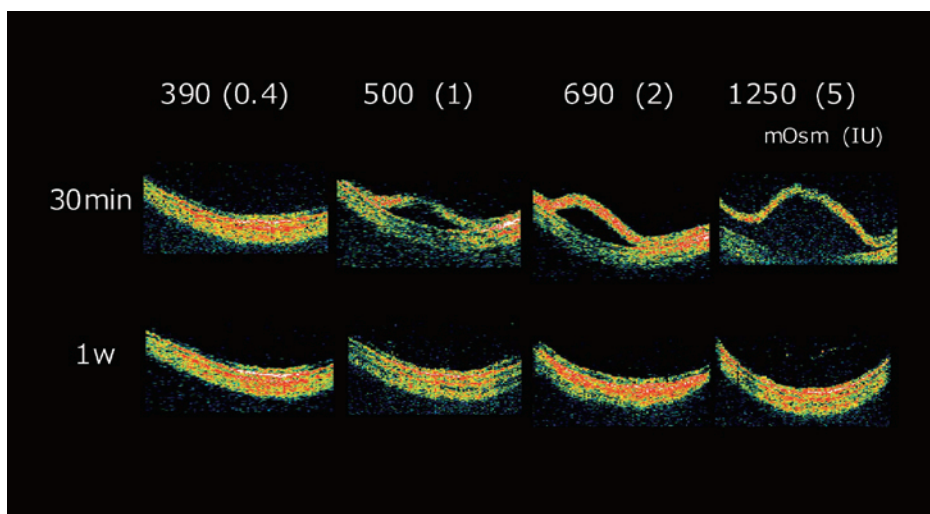


Fig. 3 Optical coherence tomographic images of eyes following an intravitreal injection of mannitol solution (group 2). The eyes were injected with 390 mOsm, 500 mOsm, 690 mOsm, and 1250 mOsm of mannitol solution which are the same osmolarity as 0.4 IU, 1 IU, 2 IU, and 5 IU of plasmin solution, respectively. Scan length was 11 mm.

(Above) Thirty minutes after mannitol injection, retinal detachments were detected in eyes with 500 mOsm, 690 mOsm, and 1250 mOsm.

(Bottom) All of the retinal detachments disappeared after 1 week.

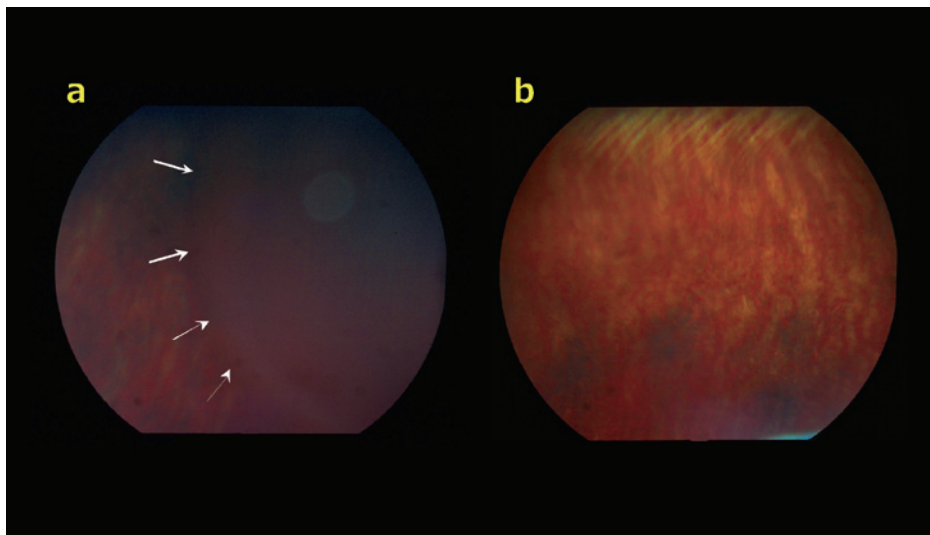


Fig. 4 Color fundus photographs before and after the injections of mannitol solution

- a. A distinct retinal detachment (arrows) can be seen 30 minutes after the injection of 1250mOsm of mannitol solution.
- b. One week after the injection, the retinal detachment is not present.

DISCUSSION

Our results showed that an intravitreal injection of plasmin either with or without vitrectomy could cause PVD in rabbit eyes. OCT examination showed that the eyes injected with the higher concentrations of plasmin also developed transient RD.

The OCT images (Figures 1a and 1b) showed that the eyes receiving ≥ 1 IU of plasmin had RD that developed within 30 minutes after the injection. Similar effects could be seen after the injection of mannitol solutions (Figure 3) whose osmolarity were equivalent to the plasmin solutions. All of the RD disappeared at one week, although there was some retinal thickening remaining in the eyes without vitrectomy and in the eyes injected with 5 IU of plasmin (Figures 1, 2B, and 2C).

Marmor¹⁶⁾ demonstrated that a midvitreal injection of 0.05 ml of 1000 mOsm solution caused a rapid whitening of the posterior retina followed by the development of large RD and permanent retinal degeneration. He also reported that 0.05 ml of a 500 mOsm solution was the weakest solution that produced ophthalmoscopically detectable changes in the retina. Verstraeten *et al.*⁵⁾ also demonstrated by light microscopy that the retinal morphology and cellular structure were normal one week after the injection of 1 IU of plasmin alone or after plasmin followed by vitrectomy. These observations are consistent in part with our data showing that 1 IU of plasmin or 87.0 mg/ml of mannitol, which are both 500 mOsm, causes RD 30 minutes after the injection, and all of them are resolved in 1 week. The effects of injected solution may also depend on factors such as the volume of the injection, the location of the injection, and pattern of diffusion. The volume of the injected plasmin and mannitol (0.1 ml) was relatively large for a rabbit eye, and in order to avoid touching the lens, which is much larger than that of human, the needle was placed in the posterior part of the vitreous cavity resulting in the solution being injected toward the retina. These may be part of the reason why such a weak-osmotic solution as 500 mOsm caused RD.

HIGH OSMOLARITY EFFECT OF PLASMIN

Table 1 Number of eyes with posterior vitreous detachment in Group 1.

	BSS-plus	0.4 IU	1 IU	2 IU	5 IU
Thirty minutes					
Only injection (n=8)	0	1	0	1	2
One week					
Only injection (n=4)	0	2	2	3	2
Injection + vitrectomy (n=4)	0	2	0	1	1
Total (n=8)	0	4	2	4	3

Verstraeten *et al.*⁵⁾ also reported that a transient decrease in the electroretinogram b-wave amplitude was seen 1 hour after an injection of plasmin, and it recovered to that of the control eyes one week later. They attributed this to the effect of the high osmolality of the plasmin solution, however it might also be due to the subretinal fluid which was detected by OCT in our study but not by ophthalmoscopy. The RD in the rabbits disappeared even after the injection of 5 IU of plasmin, which is 1250 mOsm in osmolality, at 1 week. However, plasmin injected retinas appeared to be still thickened in the eyes without vitrectomy or the eyes injected with 5 IU of plasmin. Further investigations will be necessary to determine whether the morphological changes at 30 minutes lead to a permanent damage or degeneration of the retinal tissues.

The percentage of eyes that developed PVD following the injection of the different concentrations of plasmin was not significantly different for the four concentrations of plasmin tested (Table 1). Some eyes injected with 1, 2, or 5 IU of plasmin developed RD (Figure 1). From these results, 0.4 IU of plasmin seems to be the safest and most effective concentration for rabbit eyes. However, to determine how much plasmin is safe in human eyes, the differences in the vitreous volume should be taken into account because the rabbit vitreous volume is approximately 1.2 ml, in contrast to a human vitreous volume of 4 to 5 ml. Our results showed that 0.4 IU of plasmin did not induce RD in the rabbit retina. Therefore in human eyes, plasmin enzyme up to 2 IU may be safe.

There are a number of factors other than the vitreous volume that would affect the plasmin-injected retina, e.g., location of the injection, the pattern of diffusion within the eye, and possibly physiologic, vascular or hydrodynamic characteristics of the particular eye.¹⁶⁾ Therefore, these factors have to be taken into considerations before plasmin is used on human eyes.

The efficacy of recombinant microplasmin for chemical PVD formation has been reported.¹⁷⁾ The molarity of the microplasmin needed to digest the substrate is same as that of human plasmin. Therefore, the osmolality of microplasmin injected to the eye is similar to that of human plasmin, and the intravitreal microplasmin might have similar adverse effects on retina due to its osmolality.

In conclusion, OCT images have shown that eyes injected with high concentrations of plasmin develop transient RD, which was most likely caused by the high osmolality of the plasmin solution. The RD disappeared at 1 week either with or without vitrectomy. We conclude that plasmin may be safe in separating the vitreous cortex from the retina if it is used in low concentrations.

ACKNOWLEDGEMENTS

The authors thank to Professor Duco Hamasaki of the Bascom Palmer Eye Institute of the University of Miami for his critical discussion and final manuscript revision.

This work was supported by JSPS KAKENHI Grant Number 13307048, No.14370557, No.14370556 and No. B 19791262.

REFERENCES

- 1) Liotta LA, Goldfarb RH., Brundage R, Siegal GP, Terranova V, Garbisa S. Effect of plasminogen activator (Urokinase), plasmin, and thrombin on glycoprotein and collagenous components of basement membrane. *Cancer Res*, 1981; 41: 4629–4636.
- 2) Han DP, Abrams GW, Aaberg TM. Surgical excision of the attached posterior hyaloid. *Arch Ophthalmol*, 1988; 106: 998–1000.
- 3) Russell SR, Hageman GS. Optic disc, foveal, and extrafoveal damage due to surgical separation of the vitreous. *Arch Ophthalmol*, 2001; 119: 1653–1658.
- 4) Vander JF, Kleiner R. A method for induction of posterior vitreous detachment during vitrectomy. *Retina*, 1992; 12: 172–173.
- 5) Verstraeten TC, Chapman C, Hartzler M, Winkler BS, Trese MT, Williams GA. Pharmacologic induction of posterior vitreous detachment in the rabbit. *Arch Ophthalmol*, 1993; 111: 849–854.
- 6) Hikichi T, Yanagiya N, Kado M, Akiba J, Yoshida A. Posterior vitreous detachment induced by injection of plasmin and sulfur hexafluoride in the rabbit vitreous. *Retina*, 1999; 19: 55–58.
- 7) Gandorfer A, Putz E, Welge-Lüssen U, Grüterich M, Ulbig M, Kampik A. Ultrastructure of the vitreoretinal interface following plasmin assisted vitrectomy. *Br J Ophthalmol*, 2001; 85: 6–10.
- 8) Gandorfer A, Priglinger S, Schebitz K, Hoops J, Ulbig M, Ruckhofer J, Grabner G, Kampik A. Vitreoretinal morphology of plasmin-treated human eyes. *Am J Ophthalmol*, 2002; 133: 156–159.
- 9) Gandorfer A, Ulbig M, Kampik A. Plasmin-assisted vitrectomy eliminates cortical vitreous remnants. *Eye*, 2002; 16: 95–97.
- 10) Li X, Shi X, Fan J. Posterior vitreous detachment with plasmin in the isolated human eye. *Graefe's Arch Clin Exp Ophthalmol*, 2002; 240: 56–62.
- 11) Asami T, Terasaki H, Kachi S, Nakamura M, Yamamura K, Nabeshima T, Miyake Y. Ultrastructure of internal limiting membrane removed during plasmin-assisted vitrectomy from eyes with diabetic macular edema. *Ophthalmology*, 2004; 111: 231–237.
- 12) Uemura A, Nakamura M, Kachi S, Nishizawa Y, Asami T, Miyake Y, Terasaki H. Effect of plasmin on laminin and fibronectin during plasmin-assisted vitrectomy. *Arch Ophthalmol*, 2005; 123: 209–213.
- 13) Margherio AR, Margherio RR, Hartzler M, Trese MT, Williams GA, Ferrone PJ. Plasmin enzyme-assisted vitrectomy in traumatic pediatric macular holes. *Ophthalmology*, 1998; 105: 1617–1620.
- 14) Trese MT, Williams GA, Hartzler MK. A new approach to stage 3 macular holes. *Ophthalmology*, 2000; 107: 1607–1611.
- 15) Williams JG, Trese MT, Williams GA, Hartzler MK. Autologous plasmin enzyme in the surgical management of diabetic retinopathy. *Ophthalmology*, 2001; 108: 1902–1905.
- 16) Marmor MF. Retinal detachment from hyperosmotic intravitreal injection. *Invest Ophthalmol Vis Sci*, 1979; 18: 1237–1244.
- 17) Gandorfer A, Rohleder M, Sethi C, Eckle D, Welge-Lüssen U, Kampik A, Luthert P, Charteris D. Posterior vitreous detachment induced by microplasmin. *Invest Ophthalmol Vis Sci*, 2004; 45: 641–647.