

**RANGE OF MOTION DETERMINED BY  
MULTIDETECTOR-ROW COMPUTED TOMOGRAPHY  
IN PATIENTS WITH CERVICAL OSSIFICATION  
OF THE POSTERIOR LONGITUDINAL LIGAMENT**

KEIGO ITO, MD, PhD; YASUTSUGU YUKAWA, MD, PhD; MASAACKI MACHINO, MD;  
AKINORI KOBAYAKAWA, MD; and FUMIHIKO KATO, MD, PhD

*Department of Orthopedic Surgery, Chubu Rosai Hospital, Nagoya, Japan*

ABSTRACT

The purpose of this study was to measure range of motion (ROM) in patients with cervical ossification of posterior longitudinal ligament (C-OPLL) by multidetector-row computed tomography (MDCT), and to investigate the influence of dynamic factors. The study included 101 patients with C-OPLL and 99 normal control patients. Preoperative MDCT were taken in all subjects in maximum neck flexion and extension. ROM at each disc level between C2/3 and C7/T1 in sagittal view was measured. Ossification morphology at each disc segment was divided into 6 groups: covered disc, covered vertebra, unconnected vertebra, connected vertebra (continuous), connected vertebra (localized), and others. The relationship between ROM and the group of ossification morphology was also investigated. ROM of adjacent intervertebral disc in connected vertebrae (continuous and localized) and those of others were investigated for each group. The average ROM of covered disc group was significantly higher than that of connected vertebra (continuous, localized). The average ROM of connected vertebra (continuous) group was significantly lower than that of covered disc group, others group, and normal control. There was no significant difference between ROM of adjacent intervertebral disc in connected vertebrae and others, but the average ROM of the connected vertebra group was significantly lower than that of the covered disc group and normal control group. Dynamic factor was reduced at continuous segment, but it was not increased in adjacent intervertebral disc.

Key Words: Cervical ossification of posterior longitudinal ligament, Range of motion, Cervical spinal cord injuries without radiographic evidence of trauma, Multidetector-row computed tomography, Ossification morphology

INTRODUCTION

Dynamic factors have a significant role in causing cervical spondylotic myelopathy (CSM).<sup>1)</sup> In patients with cervical ossification of the posterior longitudinal ligament (C-OPLL), mild symptoms of myelopathy are experienced even if the spinal canal narrows. The pathomechanism of cervical myelopathy caused by C-OPLL remains unknown. Despite spinal stenosis (6 mm < space available for the spinal cord < 14 mm), myelopathy may not develop in patients with severe range limitations of the cervical spine.<sup>2)</sup> This possibility indicates that not only static factors but also

---

Received: September 30, 2014; accepted: January 7, 2015

Corresponding author: Keigo Ito, MD, PhD

Department of Orthopedic Surgery, Chubu Rosai Hospital, 1-10-6 Koumei, Minato-ku, Nagoya, Aichi, Japan  
TEL: 81-52-652-5511 / FAX: 81-52-653-3533, keiort@aol.com

dynamic factors, such as listhesis or hypermobility at the discontinuity of the ossified lesion, have important roles in the development of myelopathy, especially in mixed and segmental OPLLs.

Multidetector-row computed tomography (MDCT) has given a better understanding of spinal ligament ossification. Unlike the Tsuyama classification based on lateral radiographs,<sup>3)</sup> ossification morphology and bone continuity between each vertebrae are shown more clearly by MDCT. Previously, we reported<sup>4)</sup> that ossification morphology at each disc segment was divided into 3 groups: the connection department, coating part, and non-connection department of OPLL. We previously used MDCT to measure spinal cord cross-sectional areas (SCCSAs) during flexion and extension. In that report, the SCCSA did not show statistically significant differences in ossification morphology. It is possible that myelopathy is aggravated by dynamic factors, even in the connection department of OPLL. However, we did not investigate the sagittal range of motion (ROM) and ossification of the anterior longitudinal ligaments. Previously, we reported that the incidence of spinal cord injury in the stoppage department of ossification was 64%.<sup>5)</sup> However, morphology of stoppage department had been unclear.

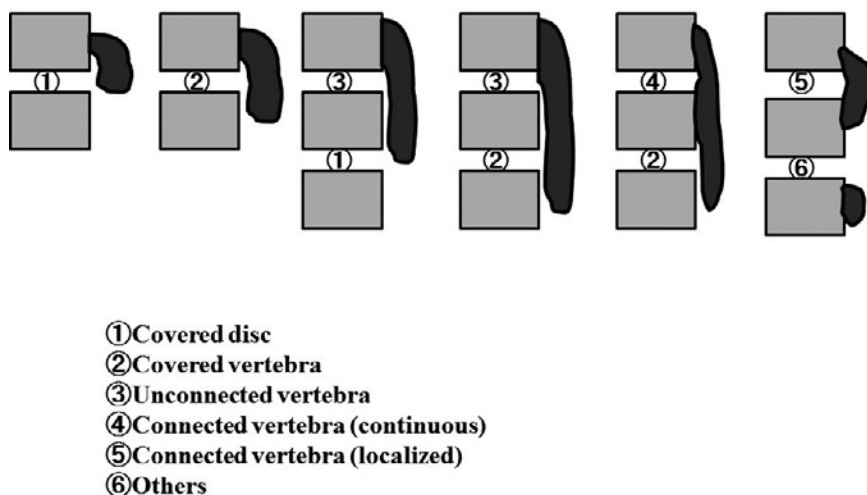
The purpose of this study was to measure ROM by MDCT, to investigate the influence of dynamic factors on the spinal cord of patients with C-OPLL. And the ROMs of adjacent intervertebral disc in connected vertebrae and those of others were investigated for each morphology.

## MATERIALS AND METHODS

From January 2006 to August 2010, a total, of 110 patients (80 men and 30 women) with C-OPLL were enrolled in this study. Their mean age was 62 years (range: 29–82 years). All patients had undergone surgical treatment for cervical myelopathy due to C-OPLL. Patients with spinal cord injury without radiological evidence of trauma were excluded. In addition, 99 patients (64 men and 35 women) who had lumbar disc herniation determined by MDCT were defined as normal controls. Patients with OPLL, fused vertebrae, and spinal instability were excluded from this normal control. Their mean age was 47 years (range: 21–77 years). This study was approved by the institutional review board. The aims of this study were explained to all patients before myelography and CT scanning, and all patients gave informed consent to their participation.

Preoperative CT scans after myelography were performed in all subjects in maximum neck flexion and extension. The position of the pillow was changed. The shoulder pillow was used in the extension.<sup>6)</sup> CT scans were obtained (1-mm-thick axial helical) with sagittal and coronal reconstruction using 64-line, multi-slice unit (Light Speed VCT; GE Healthcare Bio-Sciences, Piscataway, NJ, USA). The ROM at each disc level between C2/3 and C7/T1 in sagittal view was measured using SYNAPSE Enterprise-PACS (FUJIFILM Medical Co., Ltd., Tokyo, Japan). Ossification morphology at each disc segment was divided into 6 groups: covered disc, covered vertebra, unconnected vertebra, connected vertebra (continuous), connected vertebra (localized), and others (Fig. 1). The covered disc group was defined as comprising either cranial or caudal vertebra connected by ossification, with the other intervertebral disc not completely covered by ossification. The covered vertebra group was defined as comprising either cranial or caudal vertebra connected by ossification, with the other intervertebral disc completely covered by ossification. The unconnected vertebra group was defined as comprising either cranial or caudal vertebra connected by ossification, with ossification completely covering the vertebra, including other cranial and caudal intervertebral discs or vertebrae. The connected vertebra (continuous) group was defined as comprising both cranial and caudal vertebrae connected by ossification, of the continuous type according to the Tsuyama classification. In addition, the connected vertebra (localized) group was defined as comprising both cranial and caudal vertebrae connected by

## ROM OF PATIENTS WITH CERVICAL OPLL



**Fig. 1** Ossification morphology at each disc segment was divided into 6 groups: covered disc, covered vertebra, unconnected vertebra, connected vertebra (continuous), connected vertebra (localized), and others.

**Table 1**

|        | C2/3 | C3/4 | C4/5 | C5/6 | C6/7 | C7T1 | Total |
|--------|------|------|------|------|------|------|-------|
| C-OPLL | 3.4  | 5.9  | 7.8  | 6.4  | 5.1  | 4.0  | 28.7  |
| Normal | 6.1  | 7.4  | 9.3  | 9.6  | 8.9  | 7.6  | 48.4  |

ossification, that was the localized type according to the Tsuyama classification. The others group was defined as vertebrae with osteophytes, disc ossification, or no problematic features. The ossification morphology was defined at the biggest and longest place in much MDCT slice.

The relationship between ROM and the ossification morphology groups was also investigated. In addition, the ROMs of adjacent intervertebral disc in connected vertebrae (continuous and localized) and those of others were investigated for each group.

ROMs during neck flexion and extension were measured once on two different days by a spinal surgeon, and average values were adopted.<sup>6)</sup> The Stat View 5.0 software (ABACUS, Berkeley, CA) was used to perform data analysis. All values are expressed as the means  $\pm$  standard deviations. Analysis of variance with a post hoc test (Kruskal -Wallis test) was used to perform comparisons between the groups. A P-value  $< 0.05$  was considered to be statistically significant.

## RESULTS

The ROM results at each level are summarized in Table 1.

The ROM of the patients with C-OPLL was significantly smaller than that of the normal controls. There were 122 disc levels in the covered disc group, 114 disc levels in the covered vertebra group, 12 disc levels in the unconnected vertebra group, 40 disc levels in the connected vertebra (continuous) group, 20 disc levels in the connected vertebra (localized) group, and 340 disc levels in the others group (Fig. 2).

The average ROMs were  $6.4 \pm 4.6^\circ$  in the covered disc group,  $4.8 \pm 4.3^\circ$  in the covered

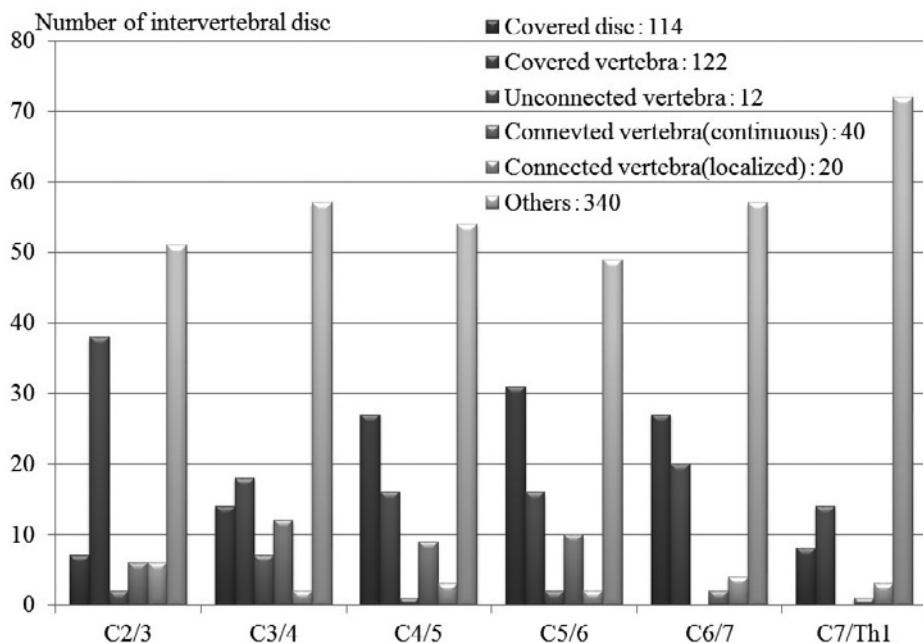


Fig. 2 Number of intervertebral disc according to each classification

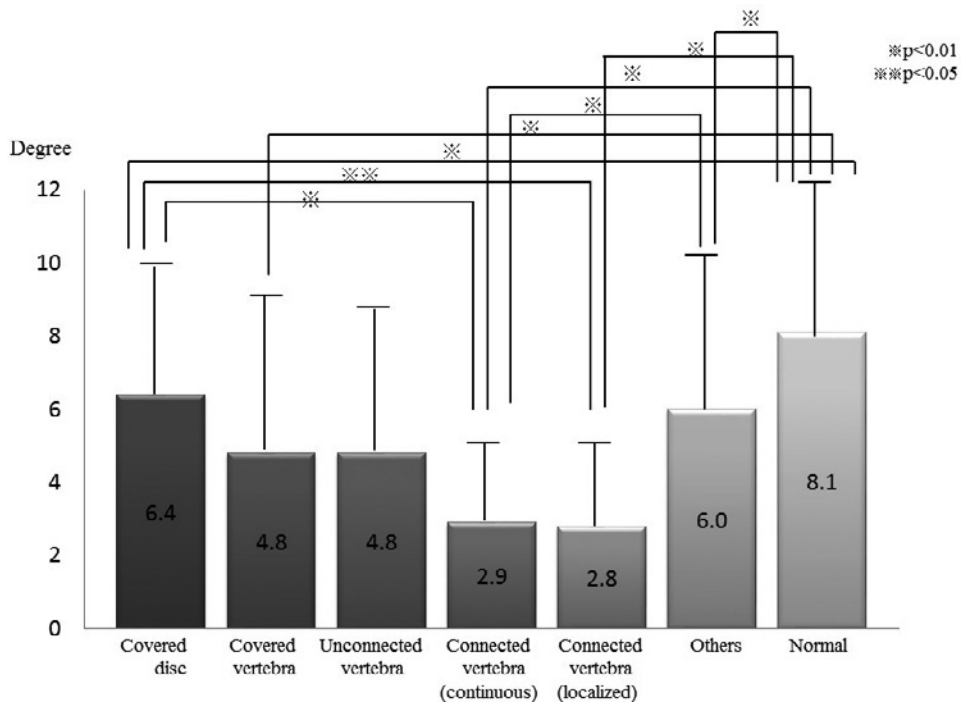


Fig. 3 The average ROM according to each classification

## ROM OF PATIENTS WITH CERVICAL OPLL

Table 2

| Number of intervertebral        | Adjacent | Others |
|---------------------------------|----------|--------|
| Covered disc                    | 35       | 87     |
| Covered vertebra                | 15       | 99     |
| Unconnected vertebra            | 4        | 8      |
| Connected vertebra (Continuous) | 17       | 23     |
| Connected vertebra (Localized)  | 9        | 11     |
| Others                          | 17       | 323    |

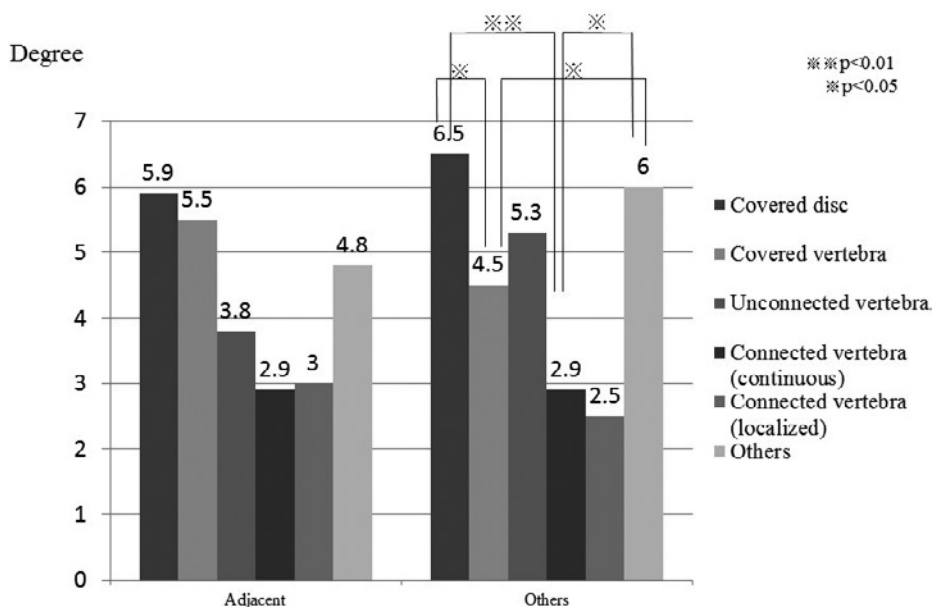


Fig. 4 The average ROM of adjacent connected vertebra (continuous and localized) and that of except adjacent connected vertebra (continuous and localized)

vertebra group,  $4.8 \pm 3.8^\circ$  in the unconnected vertebra group,  $2.9 \pm 2.3^\circ$  in the connected vertebra (continuous) group,  $2.8 \pm 2.4^\circ$  in the connected vertebra (localized) group,  $6.0 \pm 4.3^\circ$  in the others group, and  $8.1 \pm 4.2^\circ$  in the normal control. The average ROM of the covered disc group was significantly higher than that of the connected vertebra (continuous) group and connected vertebra (localized) group. In addition, the average ROM of the normal control was significantly higher than those of the covered disc group, covered vertebra group, connected vertebra (continuous), and connected vertebra (localized) groups. The average ROM of the connected vertebra (continuous) group was significantly lower than those of the covered disc group, others group, and normal control group (Fig. 3).

The average ROMs of the ROMs of adjacent intervertebral disc in connected vertebrae (continuous and localized) and those of others were investigated for each group shown in Table 2 and Fig. 4, were  $5.9 \pm 4.8^\circ$  and,  $6.5 \pm 4.6^\circ$  in the covered disc group,  $5.5 \pm 4.3^\circ$  and,  $4.5 \pm 4.3^\circ$  in the covered vertebra group,  $3.8 \pm 1.7^\circ$  and,  $5.3 \pm 4.5^\circ$  in the unconnected vertebra group,

$2.9 \pm 2.5^\circ$  and,  $2.9 \pm 2.2^\circ$  in the connected vertebra (continuous) group,  $3.0 \pm 2.5^\circ$  and,  $2.5 \pm 2.3^\circ$  in the connected vertebra (localized) group, and  $4.8 \pm 4.7^\circ$  and,  $6.0 \pm 4.3^\circ$  in the others group, respectively. There were no significant differences between the adjacent intervertebral disc in connected vertebrae and others.

## DISCUSSION

The Tsuyama classification is the most widely used criteria for classifying C-OPLL.<sup>3</sup> On the basis of lateral radiographs alone, C-OPLL can be roughly classified into 4 types: (1) continuous type, which is a continuous ossified mass extending over several vertebrae; (2) segmental type, which is a segmental ossification behind each vertebral body; (3) mixed type, which is a mixture of these 2 types; and (4) localized type, which includes other types, (e.g., circumscribed ossification of the ligament corresponding to the level of the intervertebral disc). This classification is not suitable for examining local areas. In addition, MDCT has enabled better understanding of ossification of spinal ligaments than provided by lateral radiographs, because the ossification morphology and bone continuity between each vertebrae have become clear. Previously, we had described ossification morphology at each disc segment that had been divided into 3 groups: the connection department, coating part, and non-connection department of OPLL. We had used MDCT to measure SCCSA during flexion and extension, and SCCSA did not show statistically significant differences in ossification morphology. It is possible that myelopathy is aggravated by dynamic factors, even in the connection department of OPLL.<sup>4</sup> However, those classifications were rough. Therefore, we reclassified these groups more finely, and examined ROM at each segment using a new classification. Ossification morphology at each disc segment was divided into 6 groups: covered disc, covered vertebra, unconnected vertebra, connected vertebra (continuous), connected vertebra (localized), and others. The average ROM in the covered vertebra group was quite similar to that in the unconnected vertebra group. The average ROM in the connected vertebra (continuous) was quite similar to that in the connected vertebra (localized) group. We used the former classification to classify the covered vertebra group and unconnected vertebra group as the coating part. Similarly, we had classified the connected vertebra (continuous) group and connected vertebra (localized) group as the connection department. It is not necessary to each distribute, re-classification that we increase cases is desirable.

The influence of dynamic factors on the cervical spine has been investigated by flexion–extension magnetic resonance imaging (MRI).<sup>7</sup> Dynamic factors have been proposed to be involved in the pathogenesis of CSM. However, the pathomechanism of myelopathy in C-OPLL remains unknown. Matsunaga *et al.*<sup>8,9</sup>) showed that in patients with C-OPLL, involvement of not only chronic pathological compressive factors caused by OPLL but also of circulatory and dynamic factors were thought to be important in the development and aggravation of myelopathy. Morio *et al.*<sup>10</sup>) suggested that important factors in the onset or aggravation of myelopathy are related to pathological compression by OPLL, cervical soft disc herniation, a developmentally narrow spinal canal, and a local or non-proportional hypermobility. Previously, we<sup>4</sup>) reported that SCCSA by MDCT was measured to elucidate the influence of dynamic factors. There were no significant differences in the dynamic changes of SCCSA between the connection department, coating part, and non-connection department of OPLL. It is thought that SCCSA in patients with C-OPLL gradually becomes narrower.<sup>11</sup>) It has also been suggested that the influence of dynamic factors is less in patients with mature continuous OPLL. However, this concept does not always apply to patients with continuous OPLL.

Acute spinal cord injury associated with C-OPLL can be induced by minor cervical trauma,

and there is often radiographic evidence of trauma, termed cervical spinal cord injuries without radiographic evidence of trauma (SCIWORET). Schneider *et al.*<sup>12)</sup> described the pathogenesis of central cord injury in the cervical spine as the result of a hyperextension mechanism, with subsequent compression of bony spur, a herniated disc, or a buckled ligamentum flavum.

Onishi *et al.*<sup>13)</sup> reported that SCIWORET with C-OPLL occurred at the edge of OPLL or OALL. Previously, we reported that the incidence of spinal cord injury in the stoppage department of ossification was 64%.<sup>5)</sup> However, morphology of stoppage department had been unclear. There were no significant differences between the adjacent intervertebral disc in connected vertebrae and others for each group, but the average ROM of the connected vertebra (continuous and localized) group was significantly lower than that of the covered disc group and normal control group. Dynamic factors were reduced at the continuous segment: therefore, frequency of SCIWORET at the continuous segment may be less likely to happen from other segments.

The limitations of this study were that the examination of the spinal cord changes relied on MRI signal intensities. Second, it will be necessary to examine the differences between ROM based on MDCT and ROM based on X-ray. Examination of these relationships will be necessary to help select the appropriate surgical method.

We should closely observe the natural course of patients with C-OPLL from dynamic factors even in patients with mature C-OPLL, and it will be necessary to consider SCIWORET with respect to dynamic factors.

## CONCLUSIONS

This study was performed to measure ROM in patients with C-OPLL by MDCT, and to investigate the influence of dynamic factors on the spinal cord. And ROM of adjacent intervertebral disc in connected vertebrae (continuous and localized) and those of others were investigated for each group. Ossification morphology at each disc segment was divided into 6 groups: covered disc, covered vertebra, unconnected vertebra, connected vertebra (continuous), connected vertebra (localized), and others. The average ROM of covered disc group was significantly higher than that of connected vertebra (continuous, localized). The average ROM of connected vertebra (continuous) group was significantly lower than that of covered disc group, others group, and normal control. There was no significant difference between ROM of adjacent intervertebral disc in connected vertebrae and others, but the average ROM of the connected vertebra group was significantly lower than that of the covered disc group and normal control group. Dynamic factor was reduced at continuous segment, but it was not increased in adjacent intervertebral disc.

## CONFLICT OF INTEREST

Each author certifies that they had no commercial associations (e.g., consultancies, stock ownership, equity interest/licensing arrangement, etc.) that might pose a conflict of interest in connection with the submitted article.

## REFERENCES

- 1) Sumi M, Kataoka O, Sawamura S, Ikeda M, Mukai H. Radiological analysis of cervical spondylotic myelopathy. *Rinsho seikei geka*, 1998; 33(11): 1277–1286 (in Japanese).
- 2) Liu H, Li Y, Chen Y, Wu W, Zou D. Cervical curvature, spinal cord MRIT2 signal, and occupying ratio

- impact surgical approach selection in patients with ossification of the posterior longitudinal ligament. *Eur Spine J*, 2013; 22(7): 1480–1488.
- 3) Tsuyama N. Ossification of the posterior longitudinal ligament of the spine. *Clin Orthop Relat Res*, 1984; 184: 71–84.
  - 4) Ito K, Yukawa Y, Machino M, Kato F. Spinal cord cross-sectional area during flexion and extension in the patients with cervical ossification of posterior longitudinal ligament. *Eur Spine J*, 2013; 22(11): 2564–2568.
  - 5) Ito K, Yukawa Y, Machino M, Kato F. Range of motion and spinal cord cross-sectional areas according to the ossification type of cervical ossification of posterior longitudinal ligament. *Rinsho seikei geka*, 2013; 48(9): 907–912 (in Japanese).
  - 6) Morita D, Yukawa Y, Nakashima H, Ito K, Yoshida G, Machino M, Kanbara S, Iwase T, Kato F. Range of motion of thoracic spine in sagittal plane. *Eur Spine J*, 2014 Mar; 23(3): 673–678.
  - 7) Iwasaki M, Kawaguchi Y, Kimura T, Yonenobu K. Long-term results of expansive laminoplasty for ossification of the posterior longitudinal ligament of the cervical spine: more than 10 years follow up. *J Neurosurg*, 2002; 96 (2 Suppl): 180–189.
  - 8) Matsunaga S, Nakamura K, Seichi A, Yokoyama T, Toh S, Ichimura S, Satomi K, Endo K, Yamamoto K, Kato Y, Ito T, Tokuhashi Y, Uchida K, Baba H, Kawahara N, Tomita K, Matsuyama Y, Ishiguro N, Iwasaki M, Yoshikawa H, Yonenobu K, Kawakami M, Yoshida M, Inoue S, Tani T, Kaneko K, Taguchi T, Imakiire T, Komiya S. Radiographic predictors for the development of myelopathy in patients with ossification of the posterior longitudinal ligament: a multicenter cohort study. *Spine*, 2008; 33(24): 2648–2650.
  - 9) Matsunaga S, Komiya S, Toyama Y. Risk factors for development of myelopathy in patients with cervical spondylosis cord compression. *Eur Spine J*, 2013; May 23. [Epub ahead of print]
  - 10) Morio Y, Nagashima H, Teshima R, Nawata K. Radiological pathogenesis of cervical myelopathy in 60 consecutive patients with cervical ossification of the posterior longitudinal ligament. *Spinal Cord*, 1999; 37(12): 853–857.
  - 11) Matsunaga S, Sakou T, Taketomi E, Yamaguchi M, Okano T. The natural course of myelopathy caused by ossification of the posterior longitudinal ligament in cervical spine. *Clin Orthop Relat Res*, 1994; 305: 168–177.
  - 12) Schneider RC, Cherry G, Pantek H. The syndrome of acute central cervical spinal cord injury; with special reference to the mechanisms involved in hyperextension injuries of cervical spine. *J Neurosurg*, 1954; 11(6): 546–577.
  - 13) Onishi E, Sakamoto A, Murata S, Matsushita M. Risk factors for acute cervical spinal cord injury associated with ossification of the posterior longitudinal ligament. *Spine*, 2012; 37(8): 660–666.